

Oral Histopathology

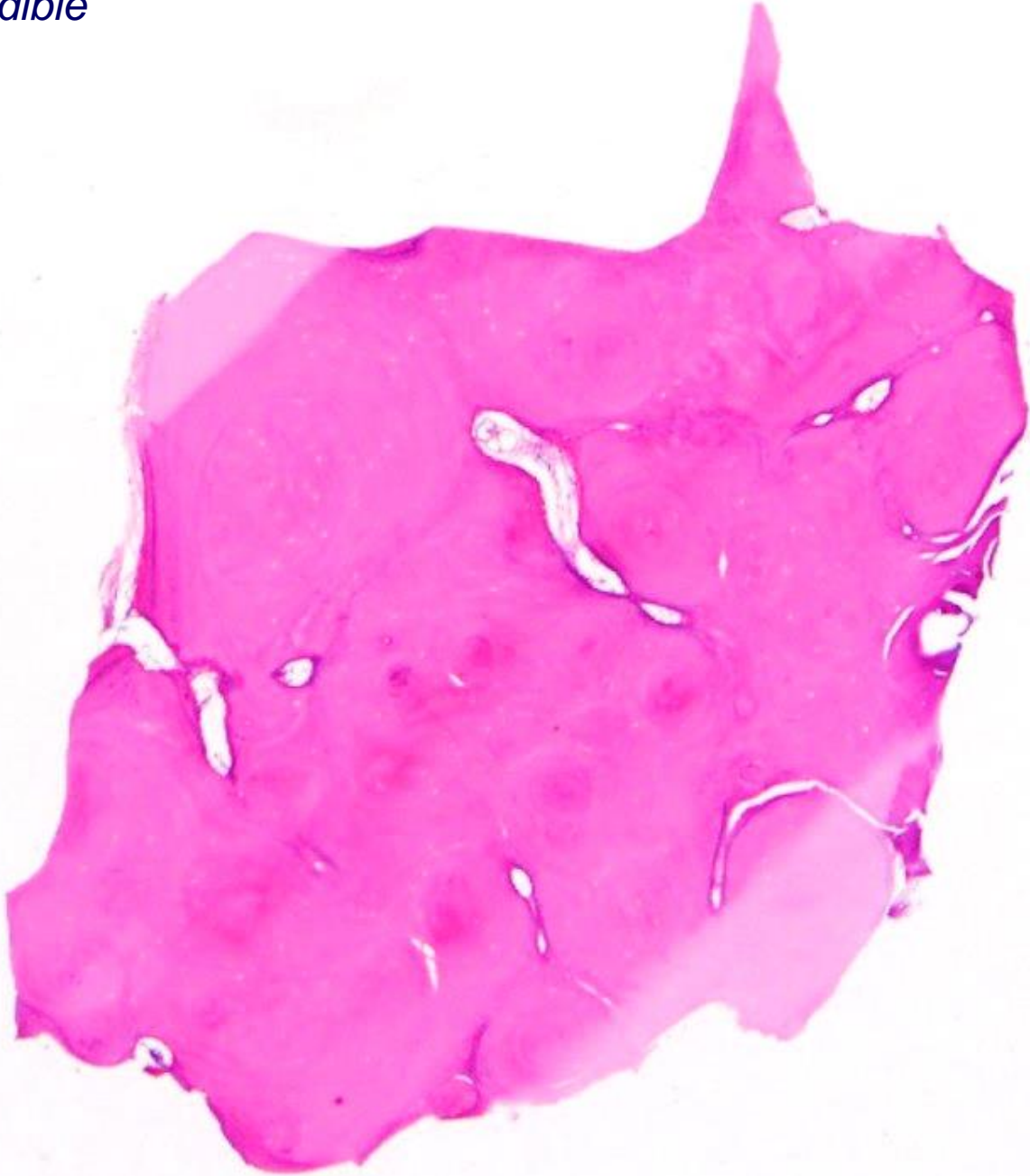
Series 17

DAVID E. KLINGMAN, DMD

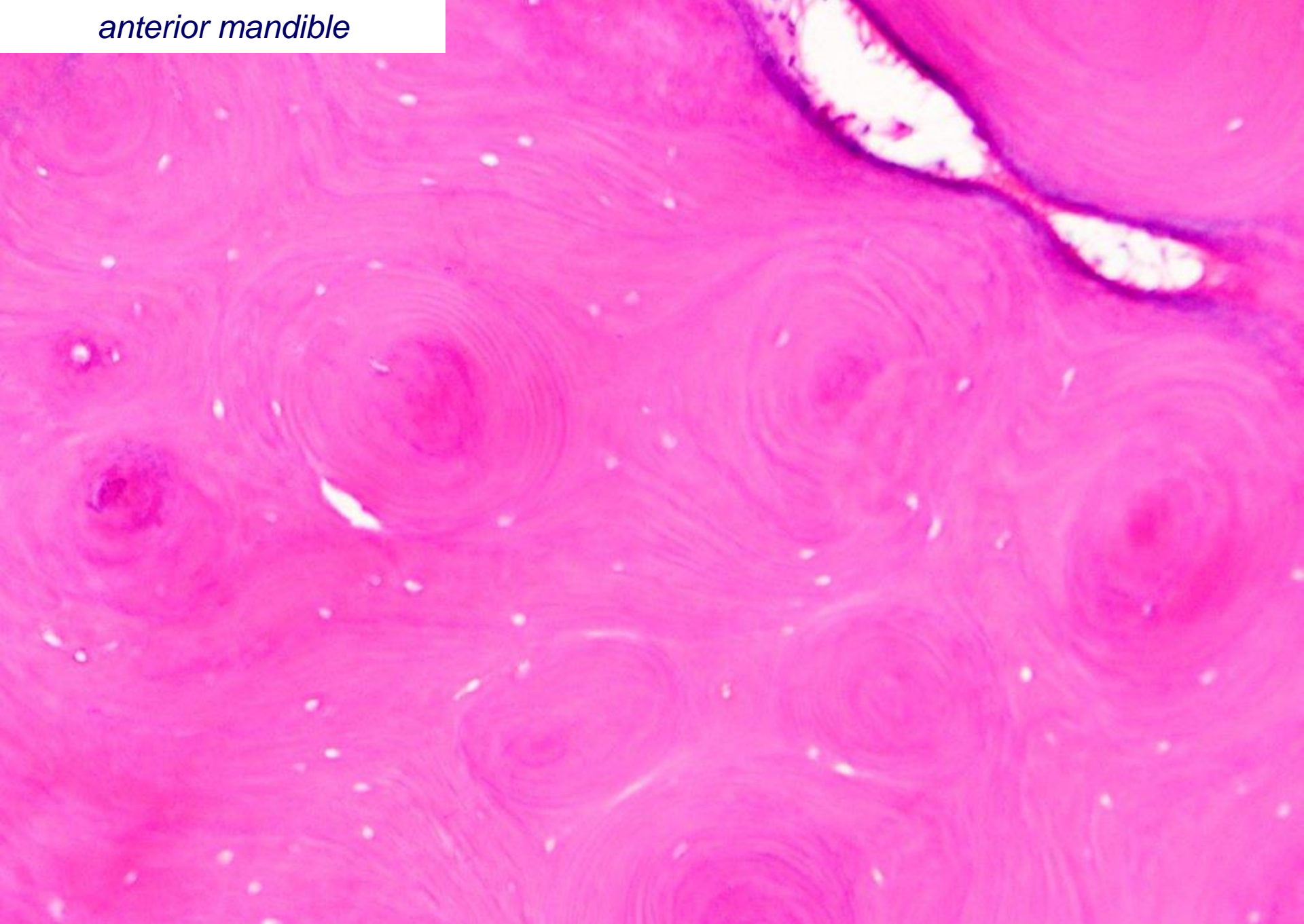
Diplomate, American Board of Oral and Maxillofacial Pathology

Diplomate, American Board of General Dentistry

anterior mandible

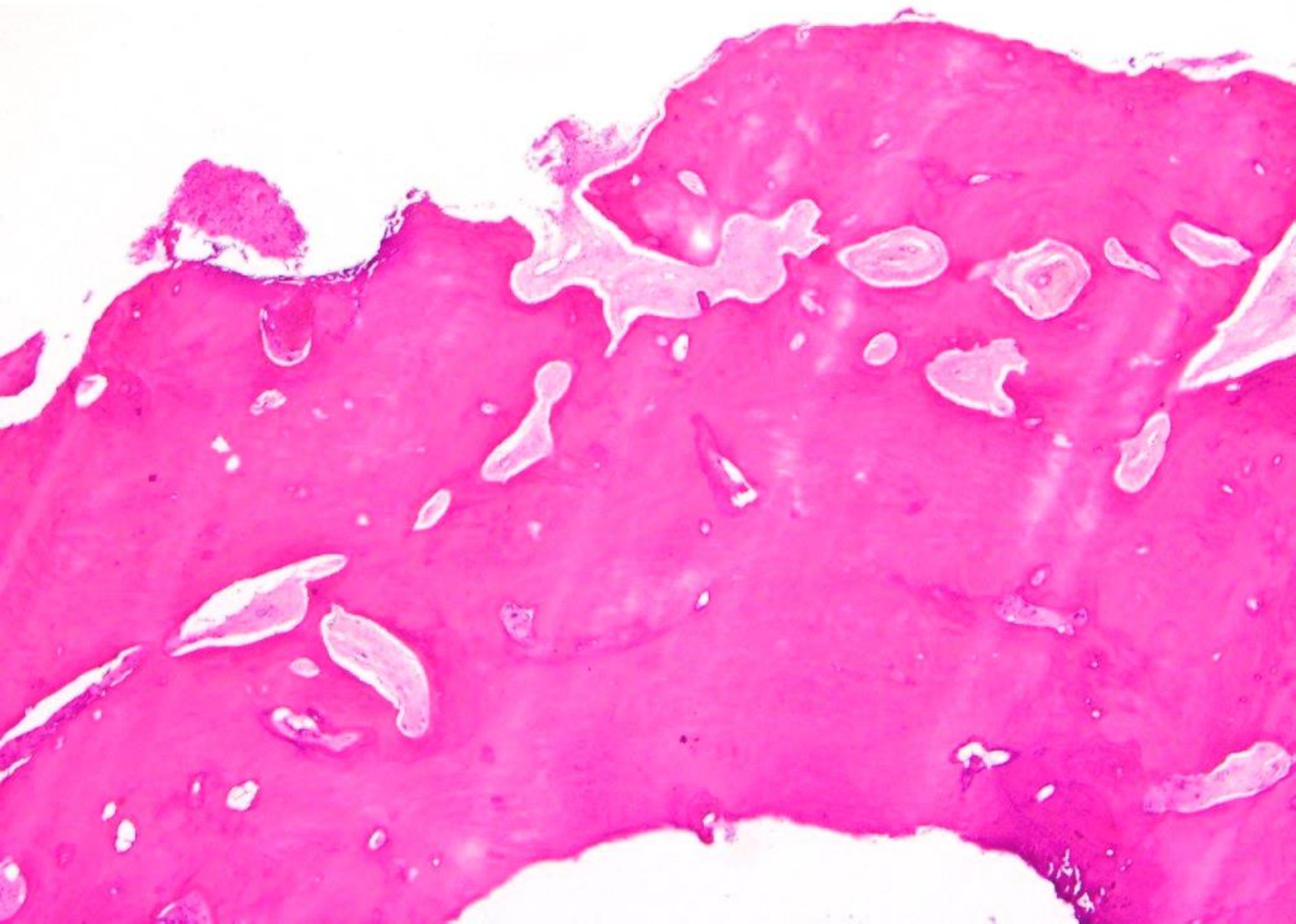


anterior mandible

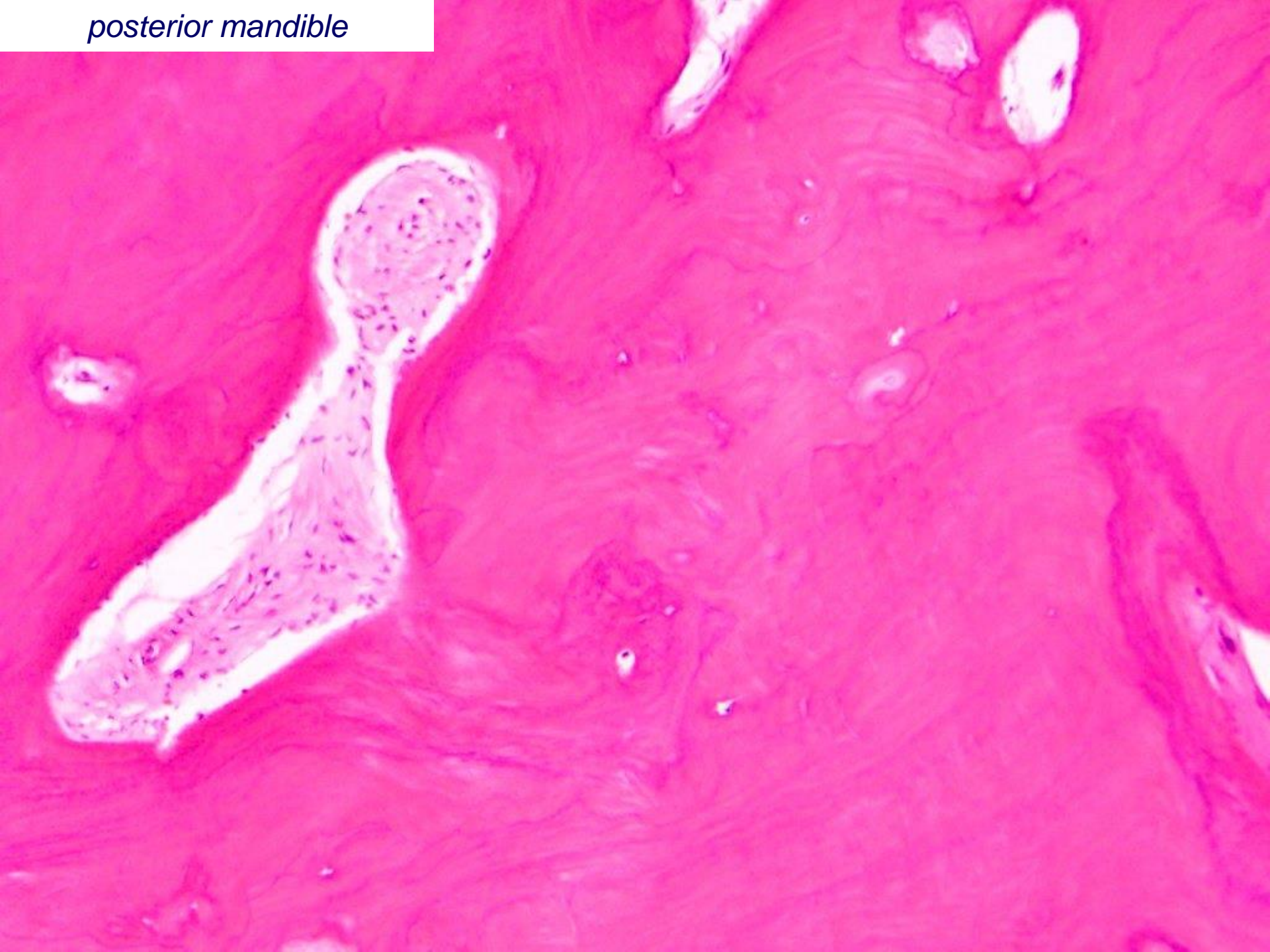


BFOL, c/w periapical cemento-osseous dysplasia

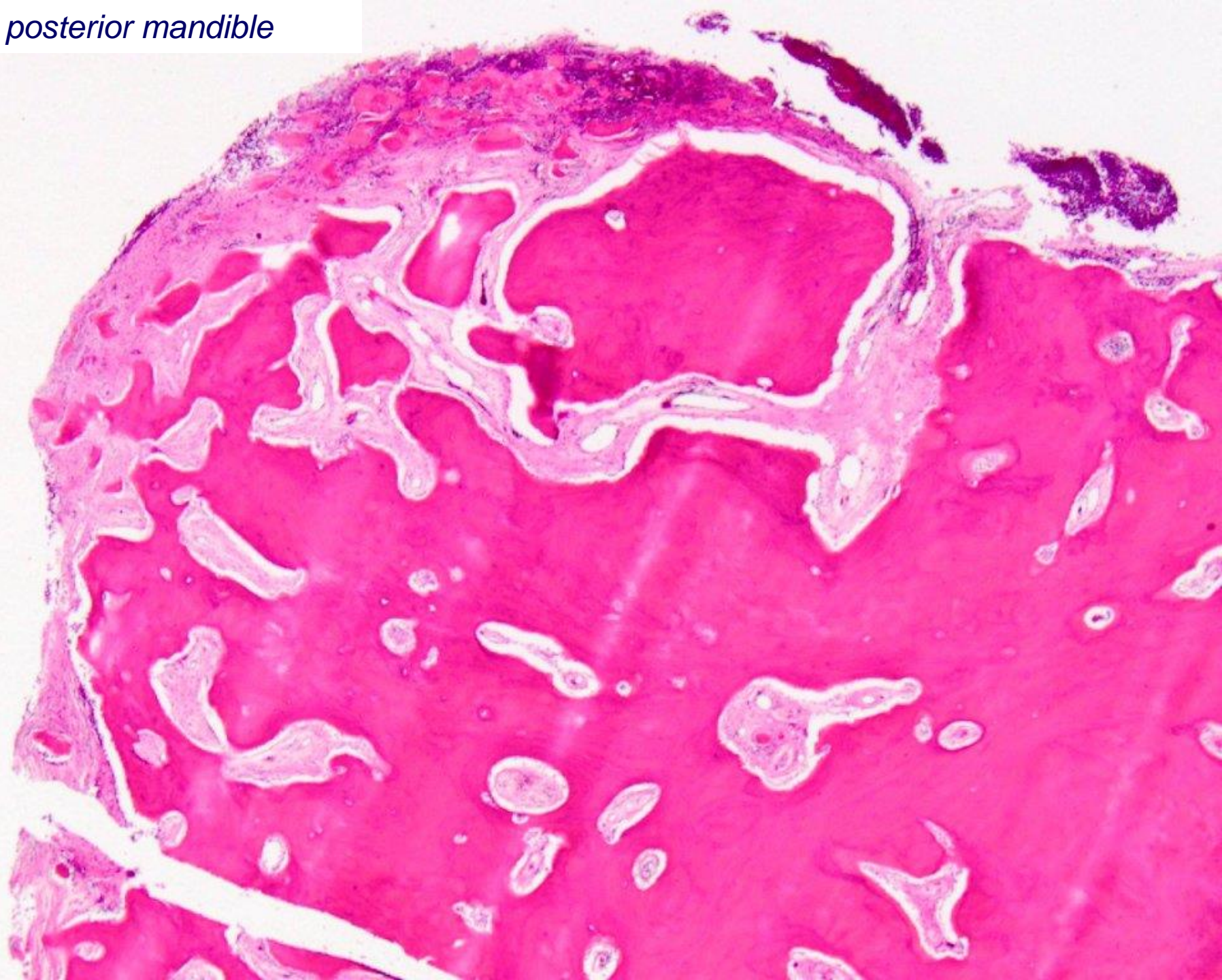
posterior mandible



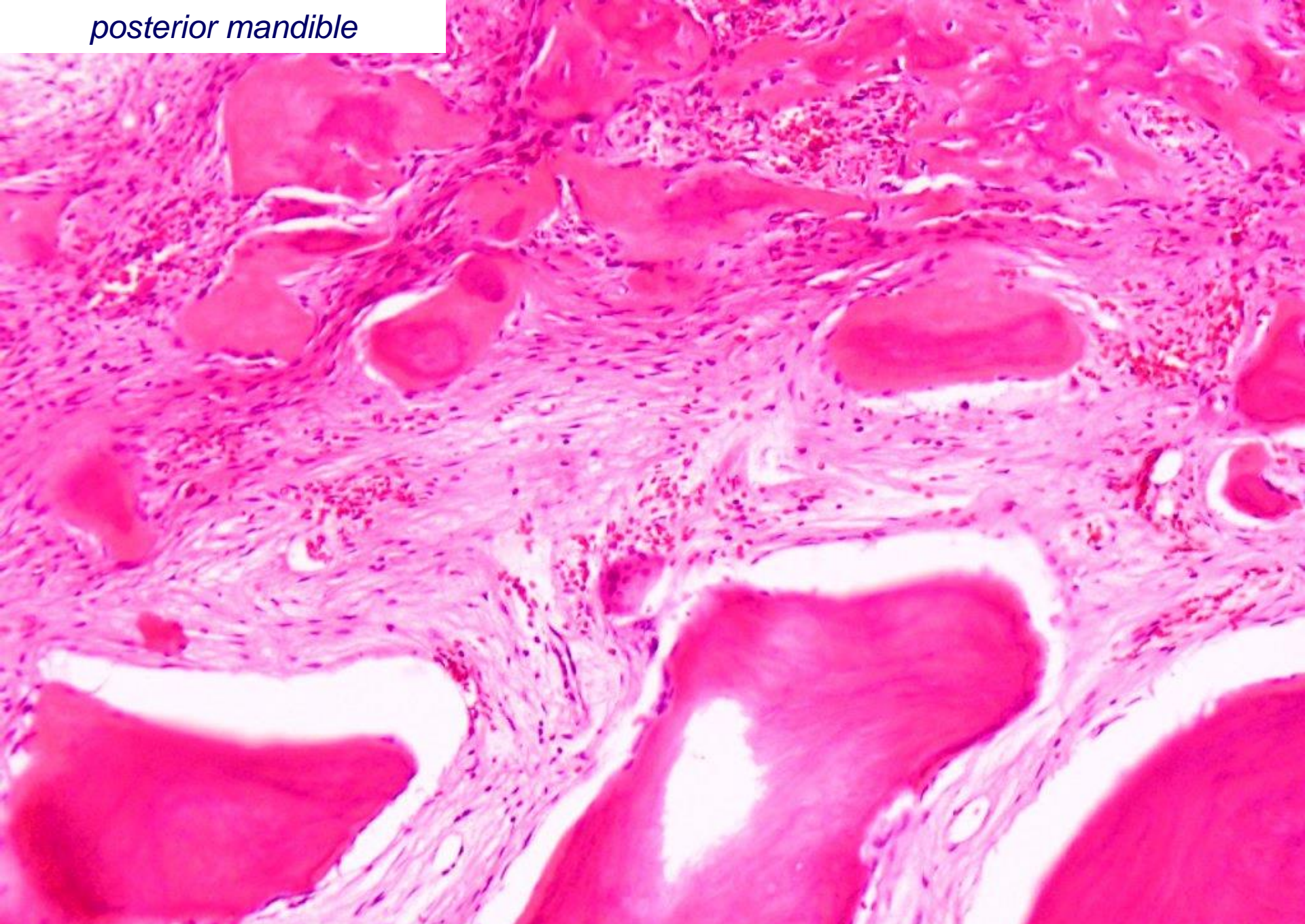
posterior mandible



posterior mandible

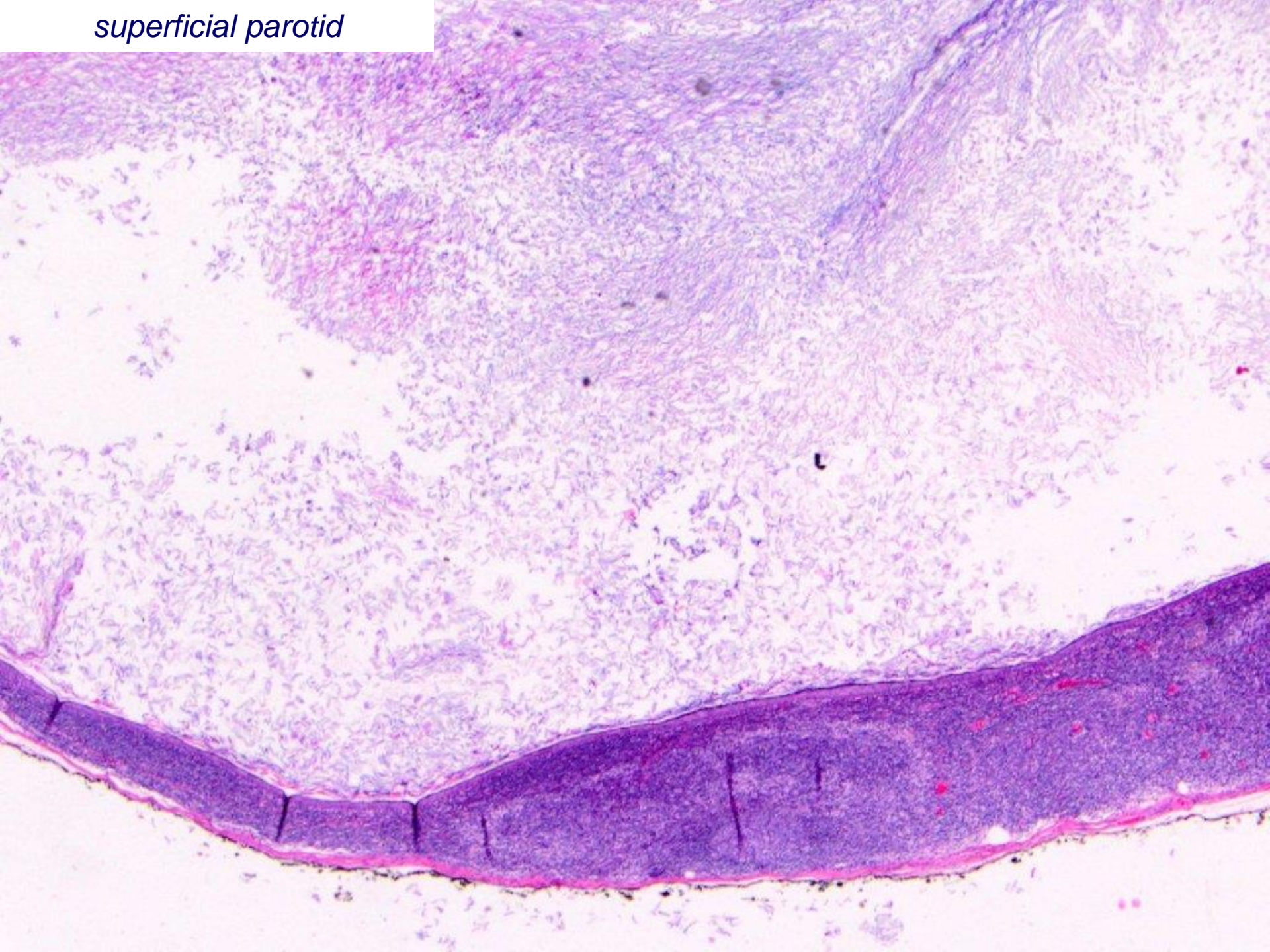


posterior mandible

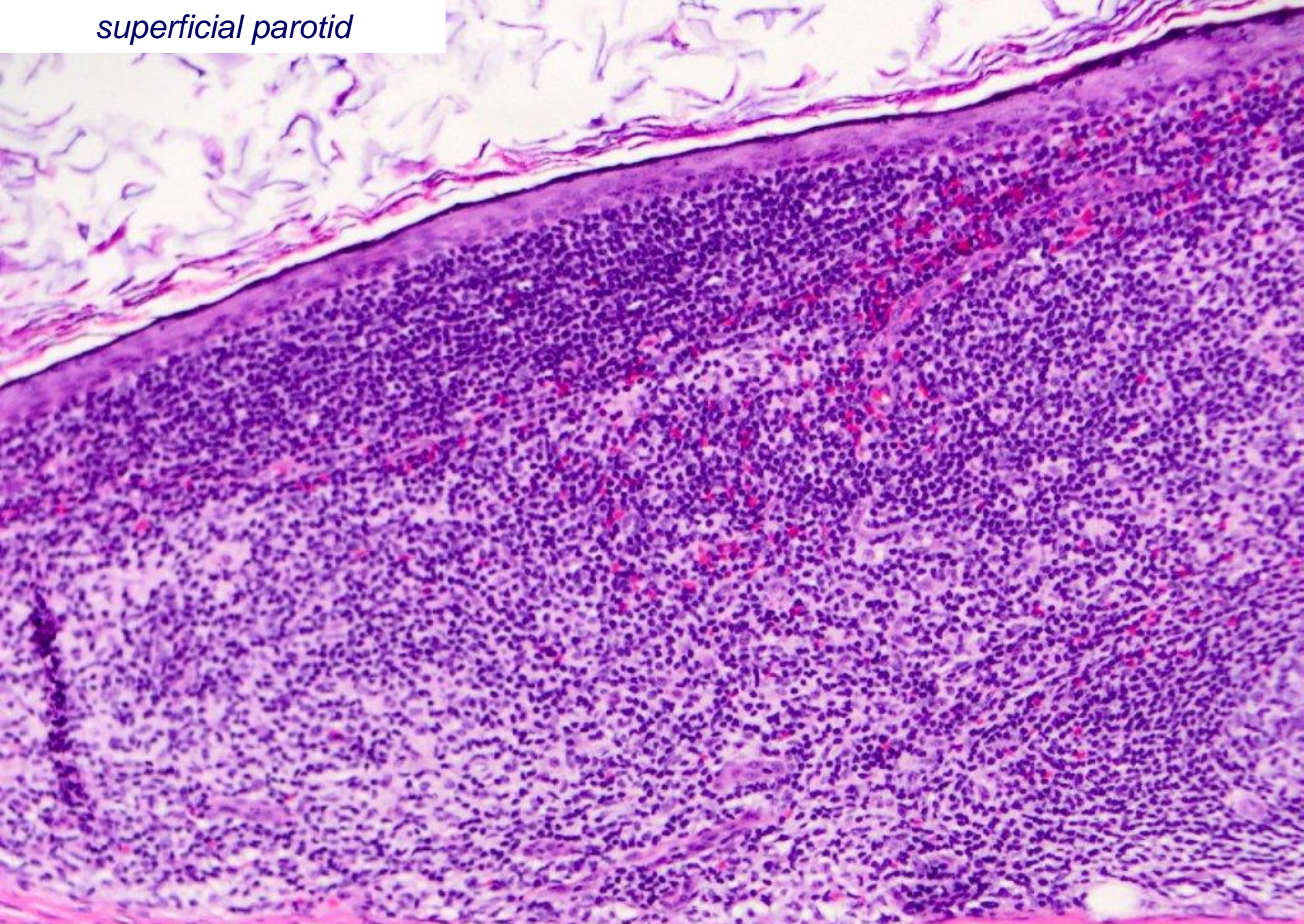


BFO, c/w focal cemento-osseous dysplasia

superficial parotid

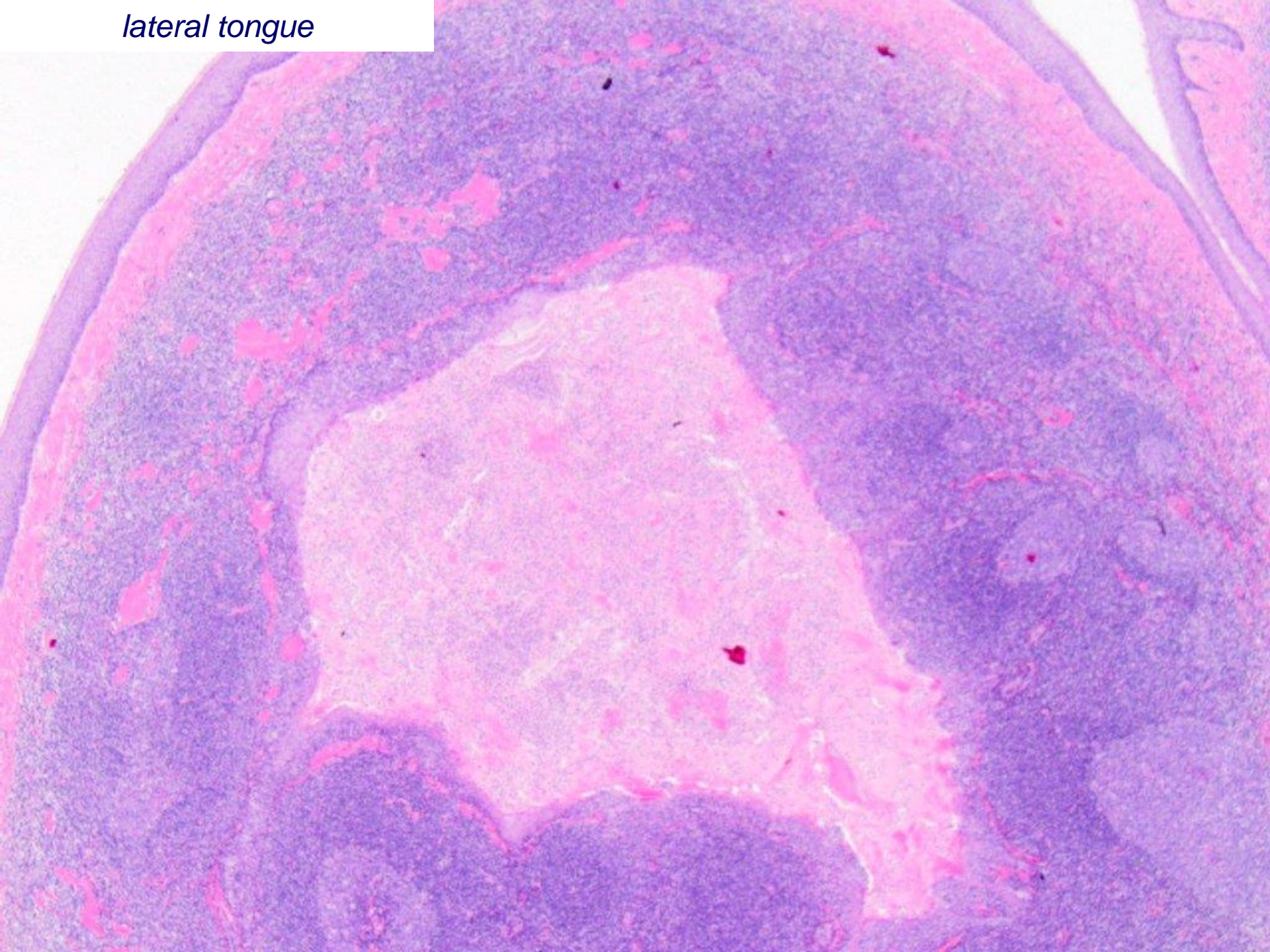


superficial parotid

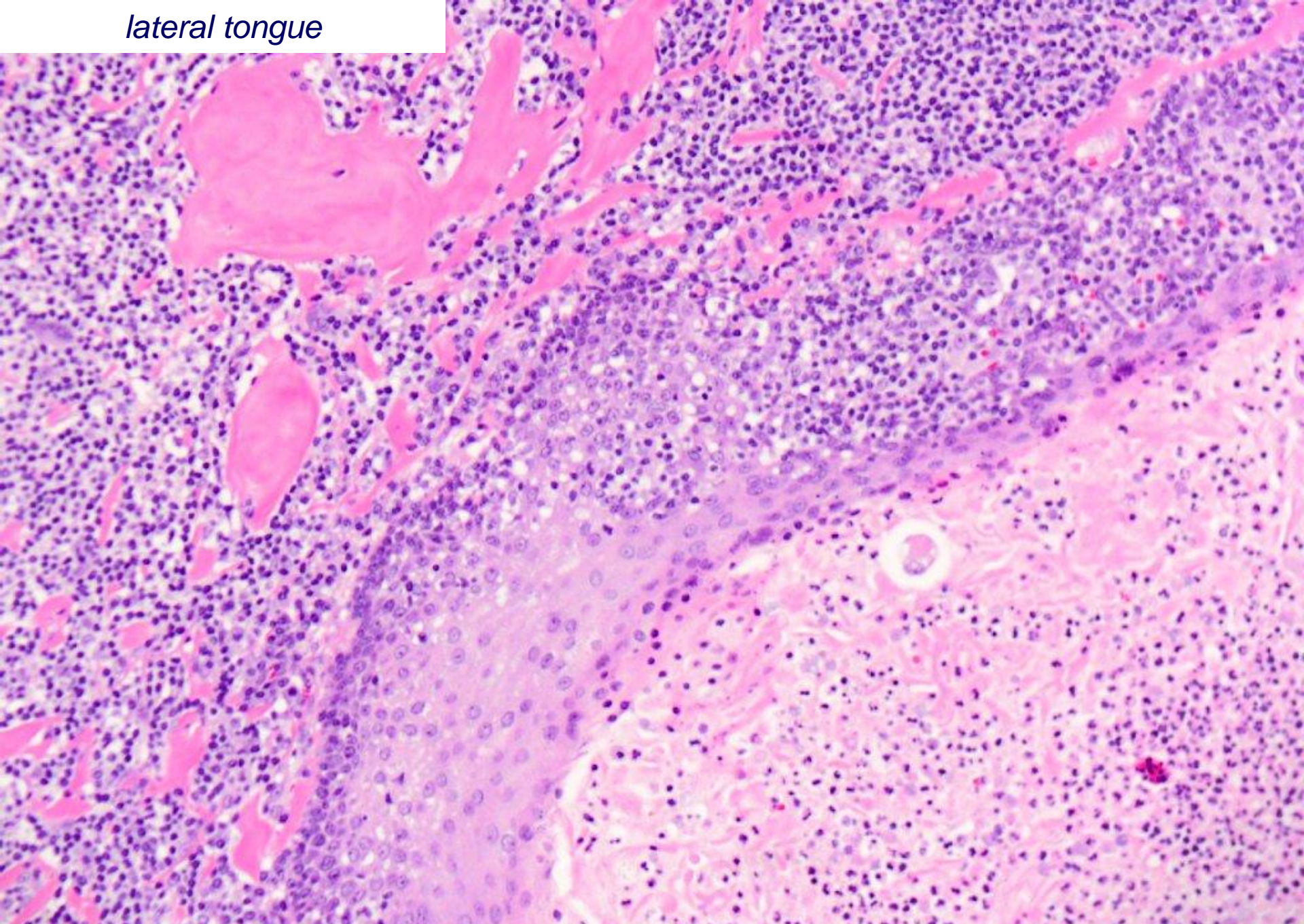


lymphoepithelial cyst

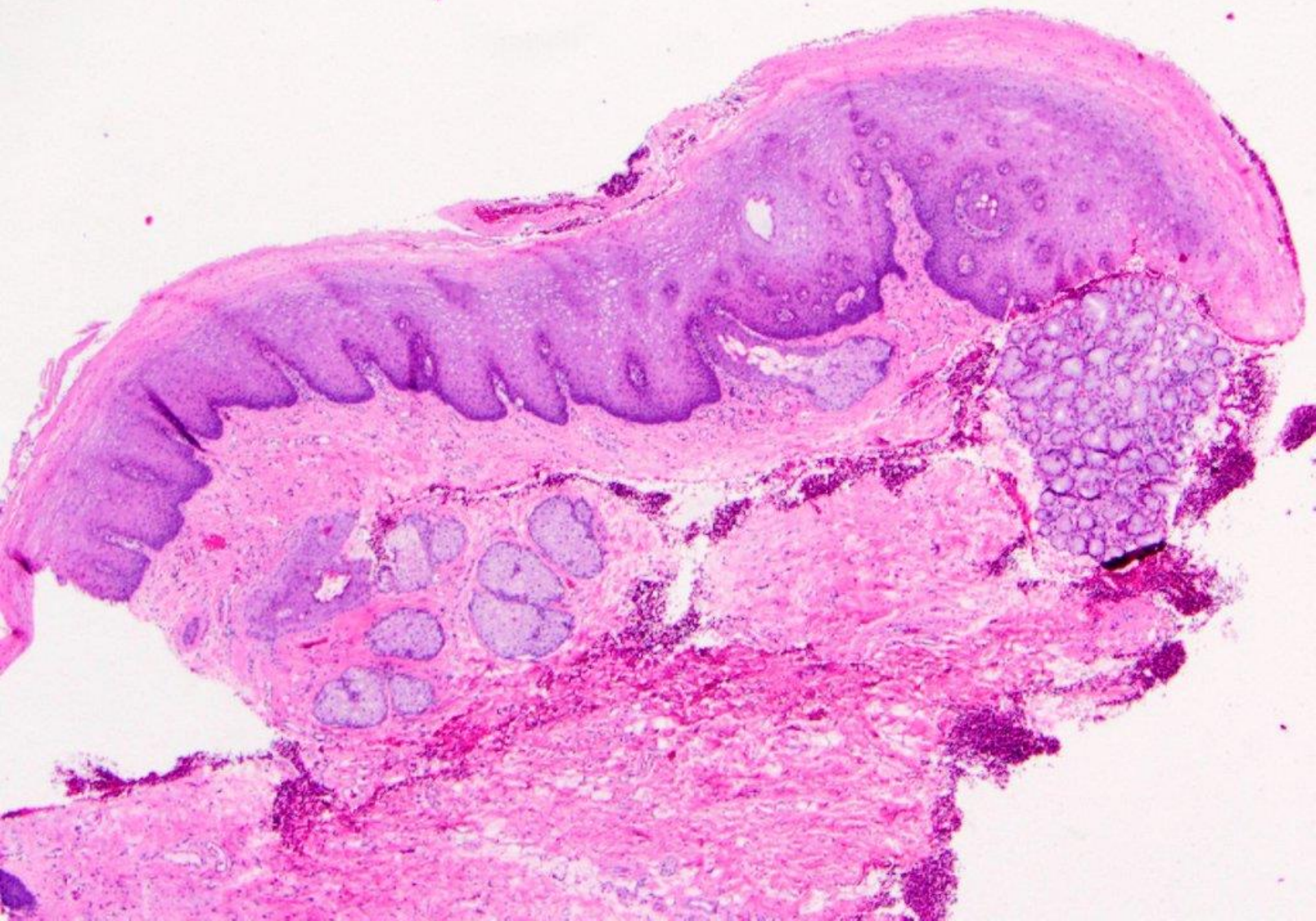
lateral tongue

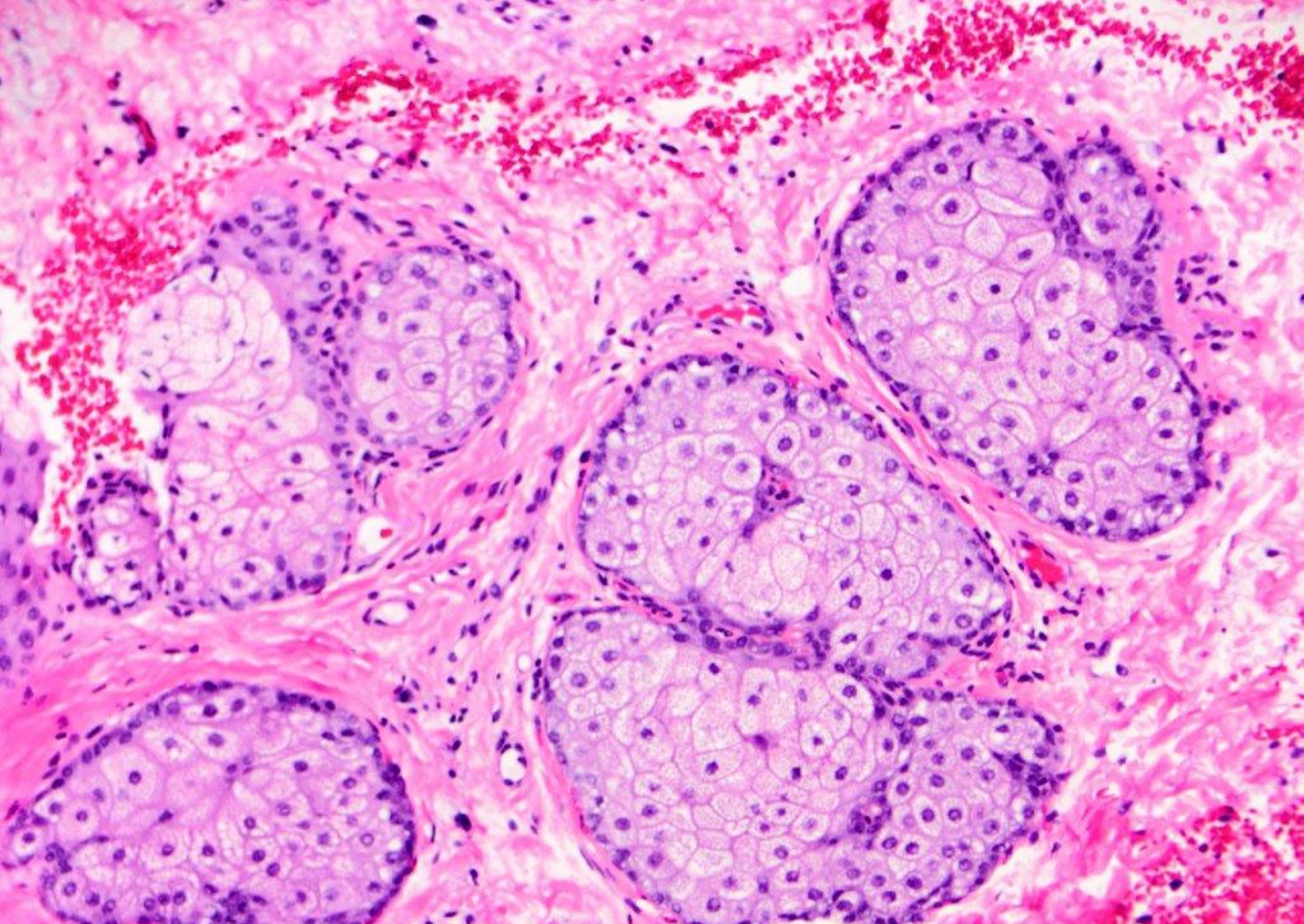


lateral tongue

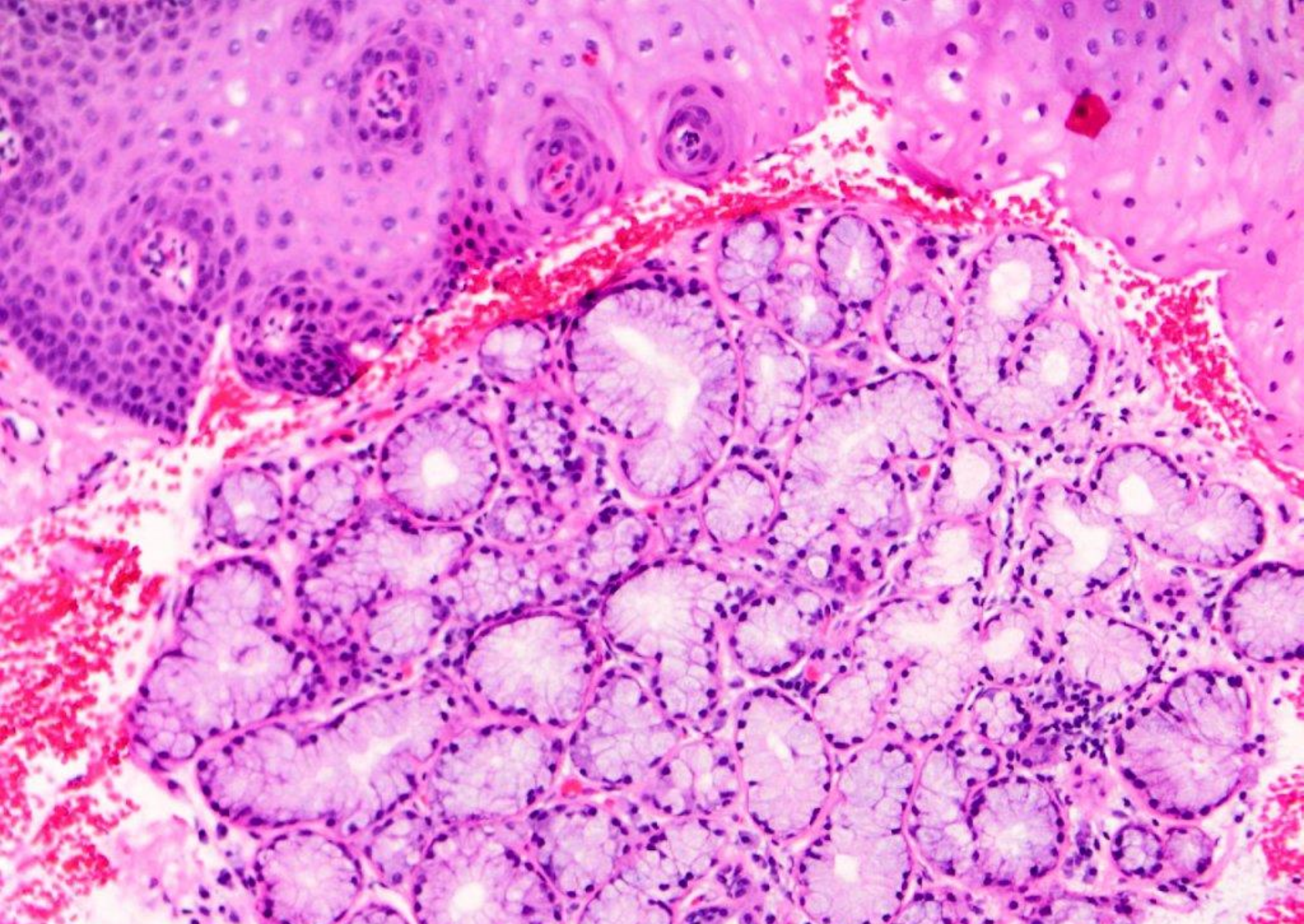


lymphoepithelial cyst

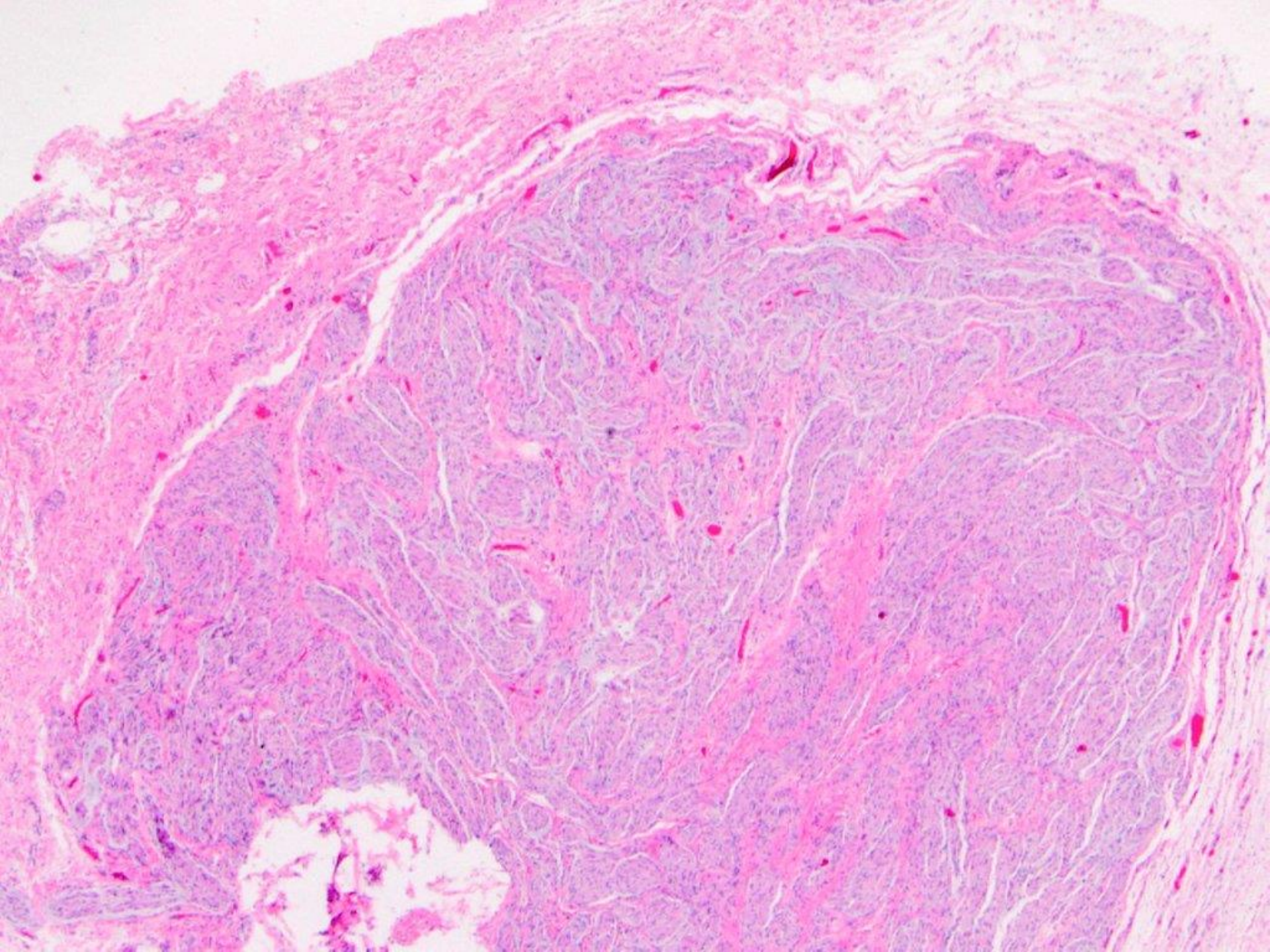


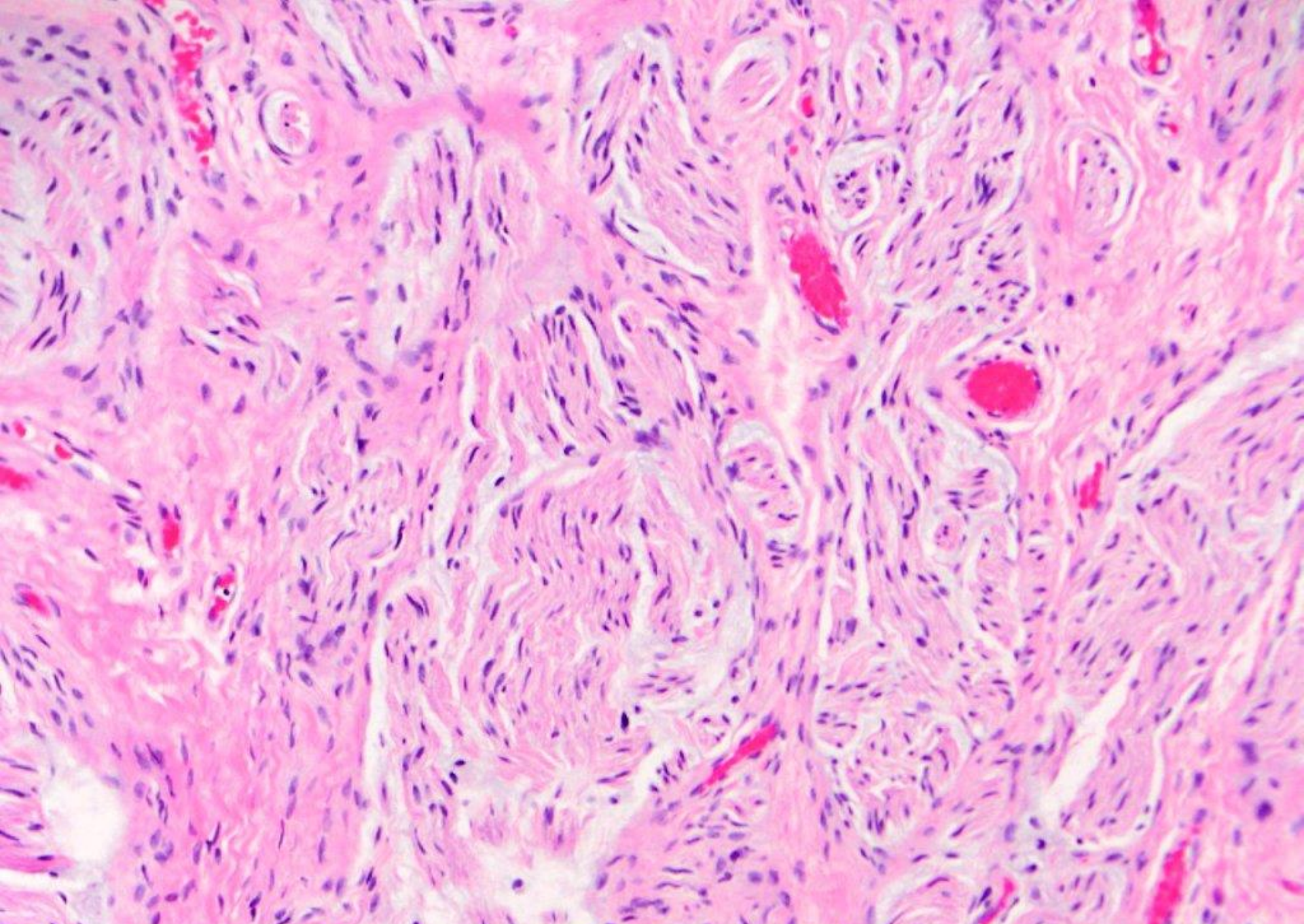


sebaceous glands (Fordyce granules)

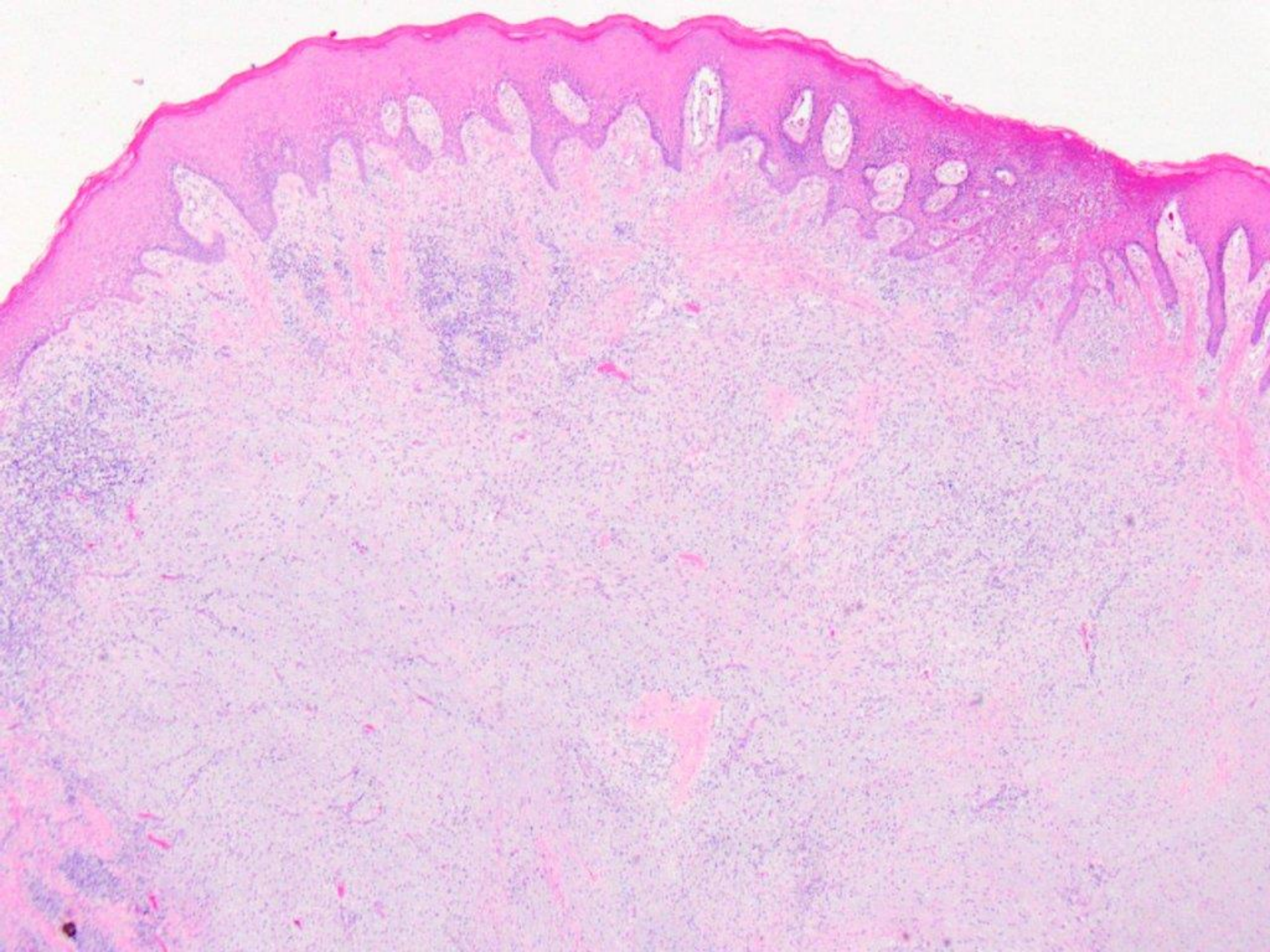


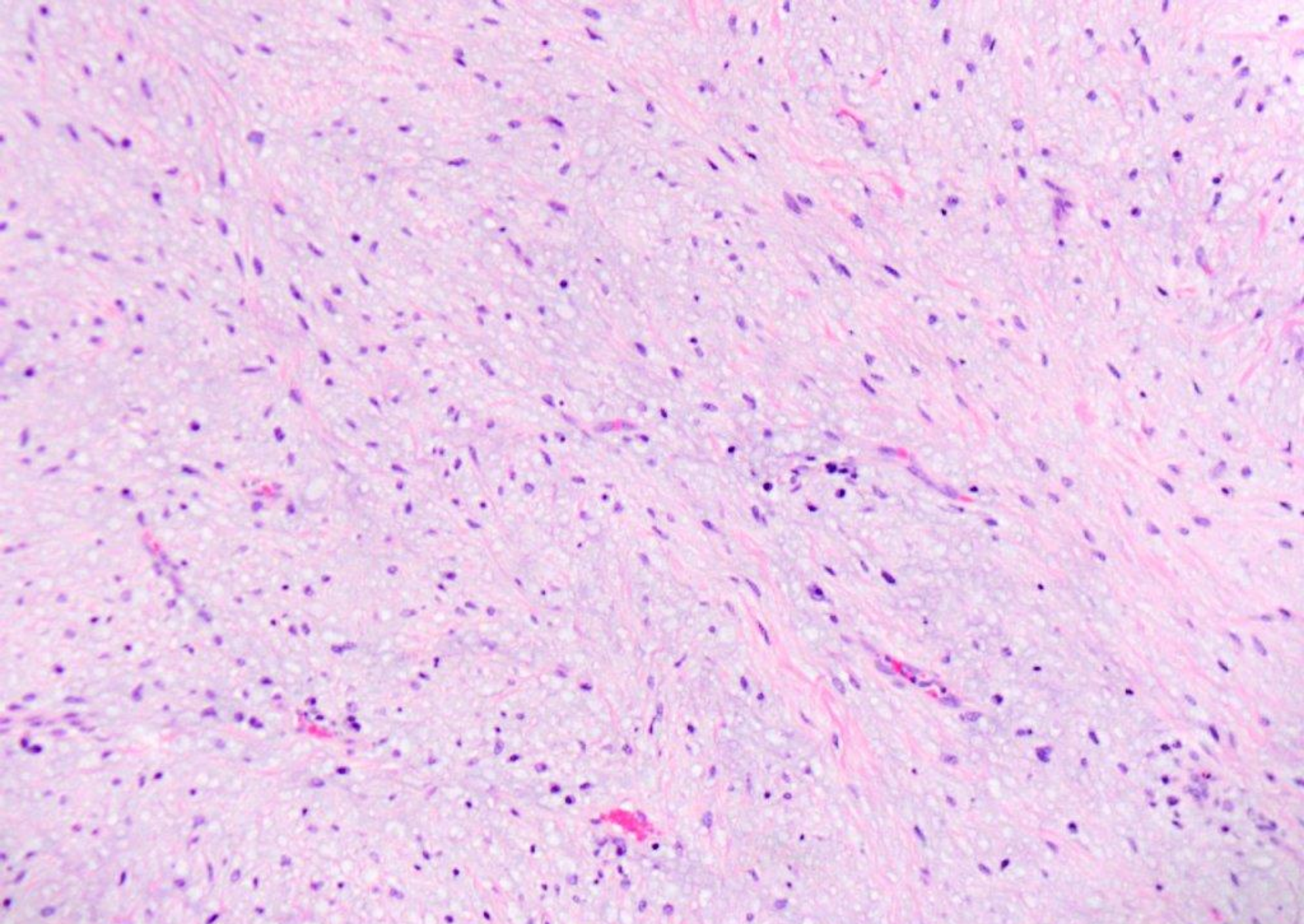
minor salivary glands



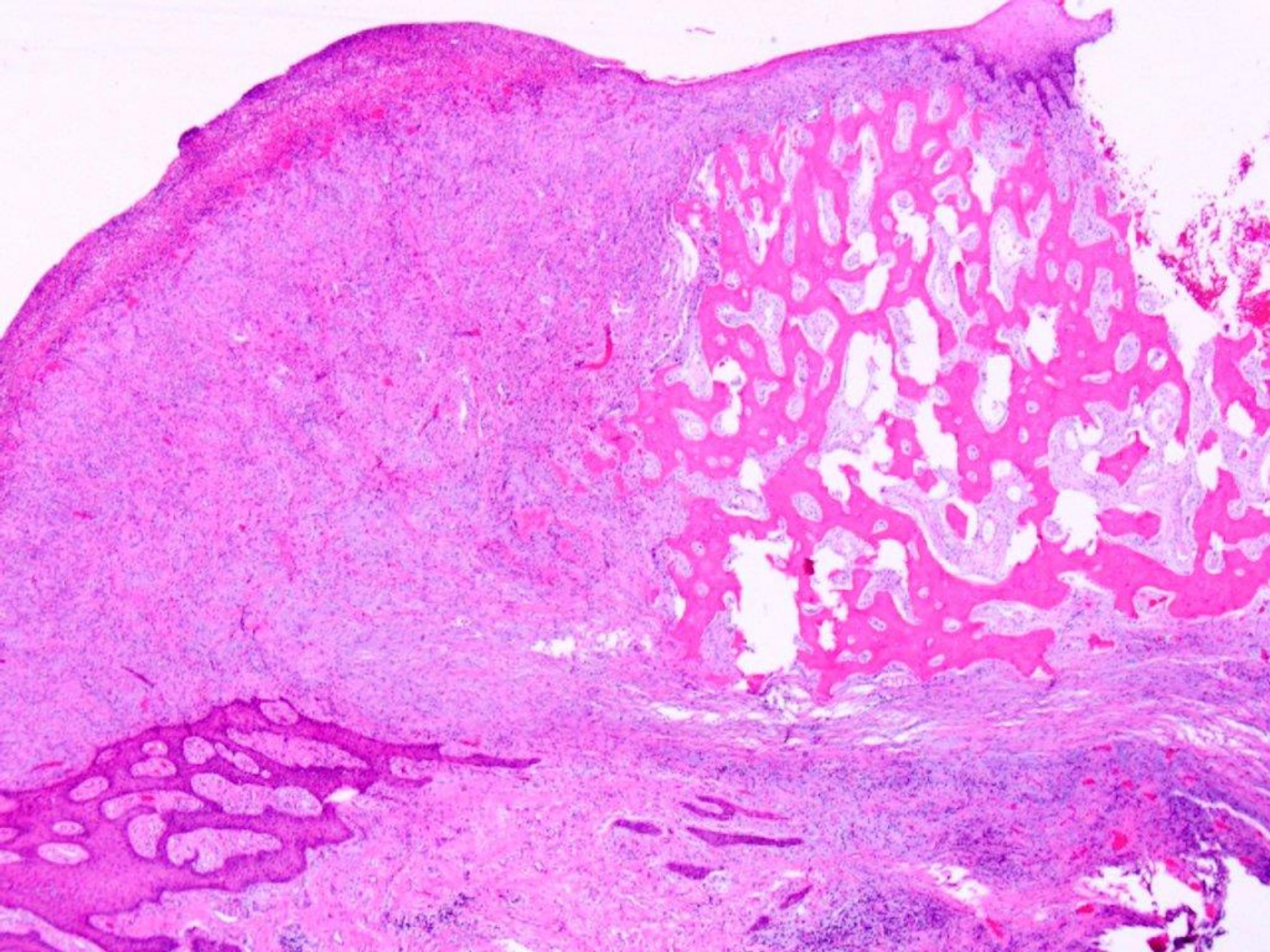


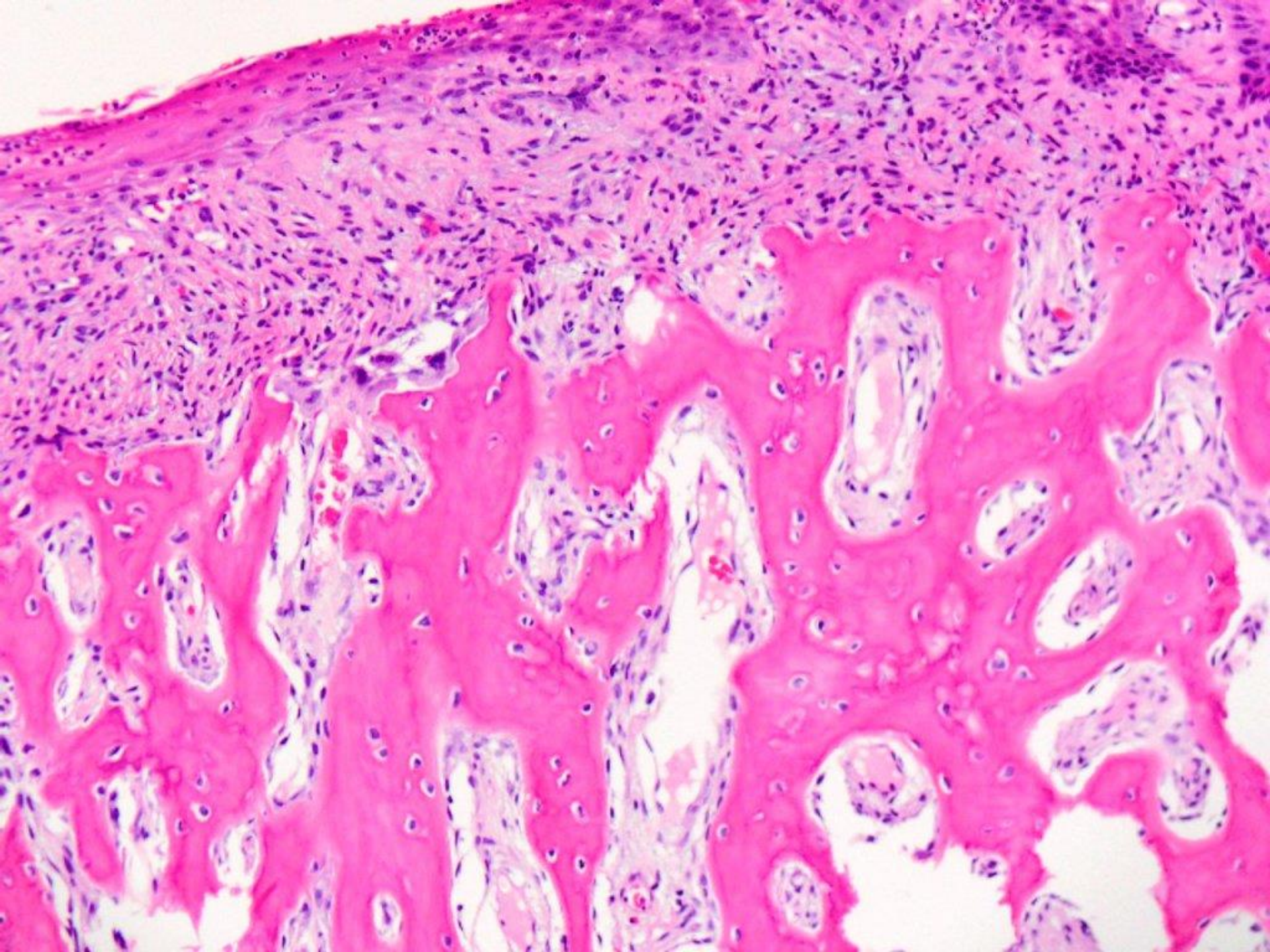
mucosal neuroma [consideration given to MEN IIb/III; serum calcitonin recommended]

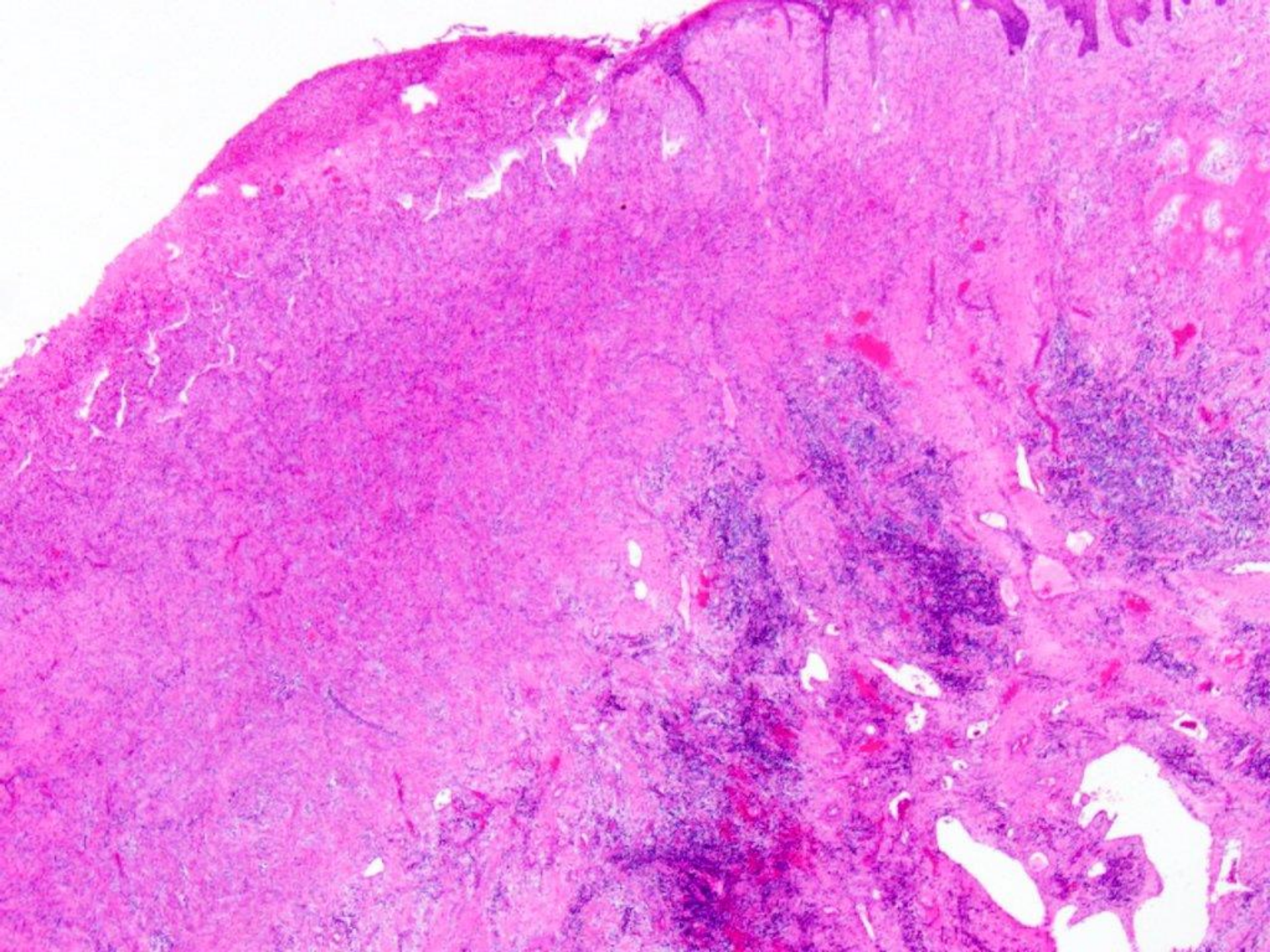


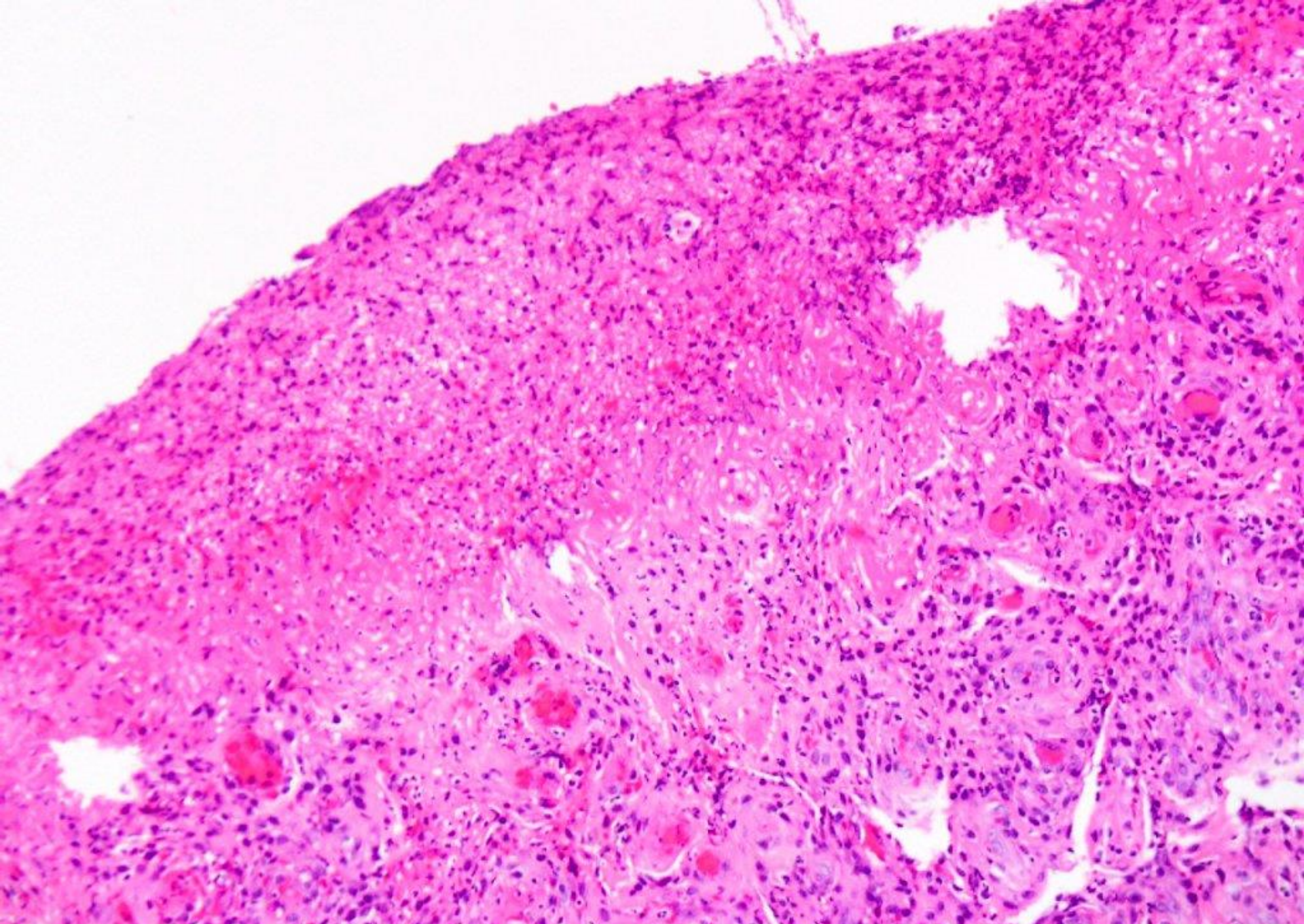


fibromyxoma

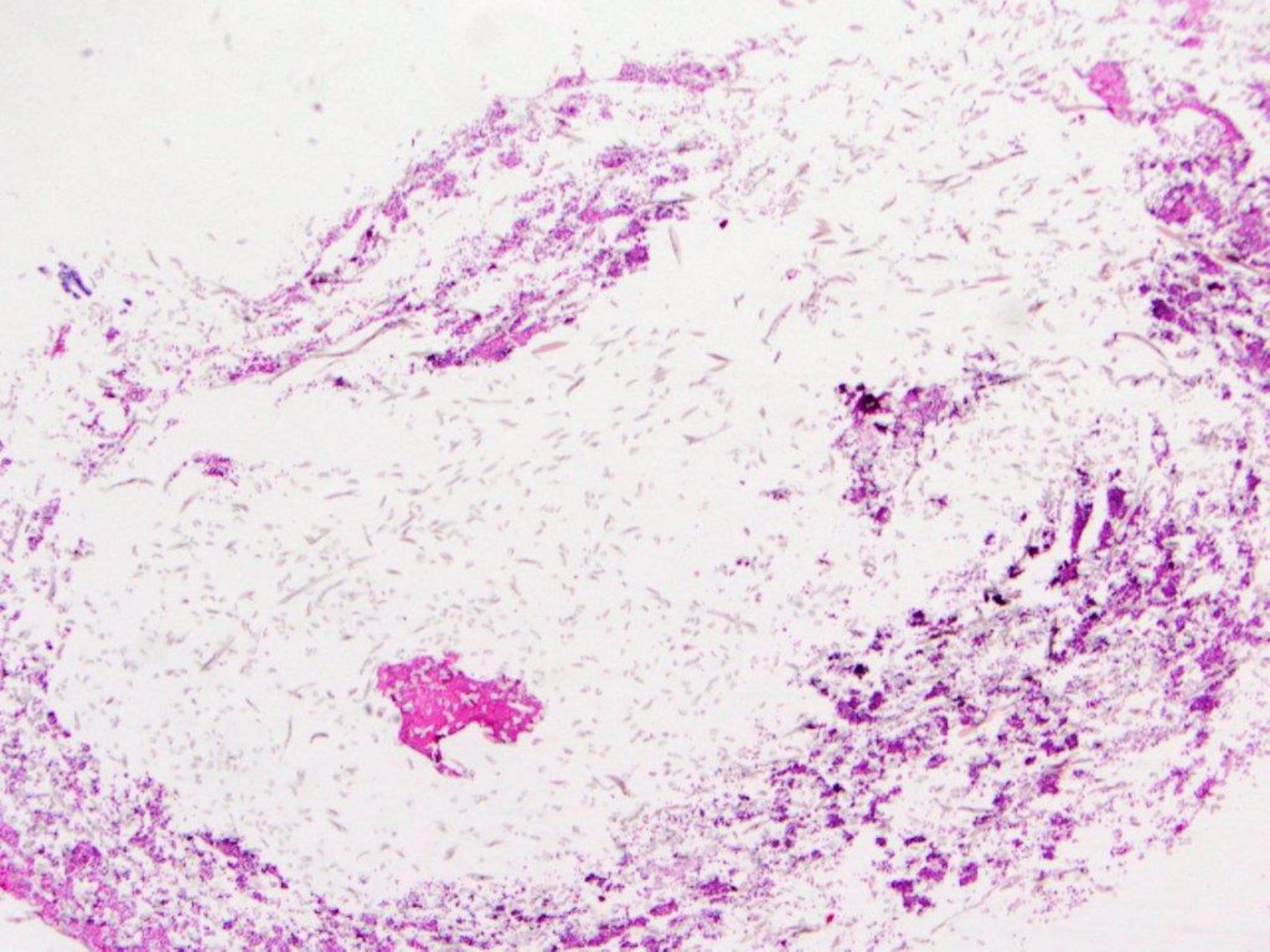


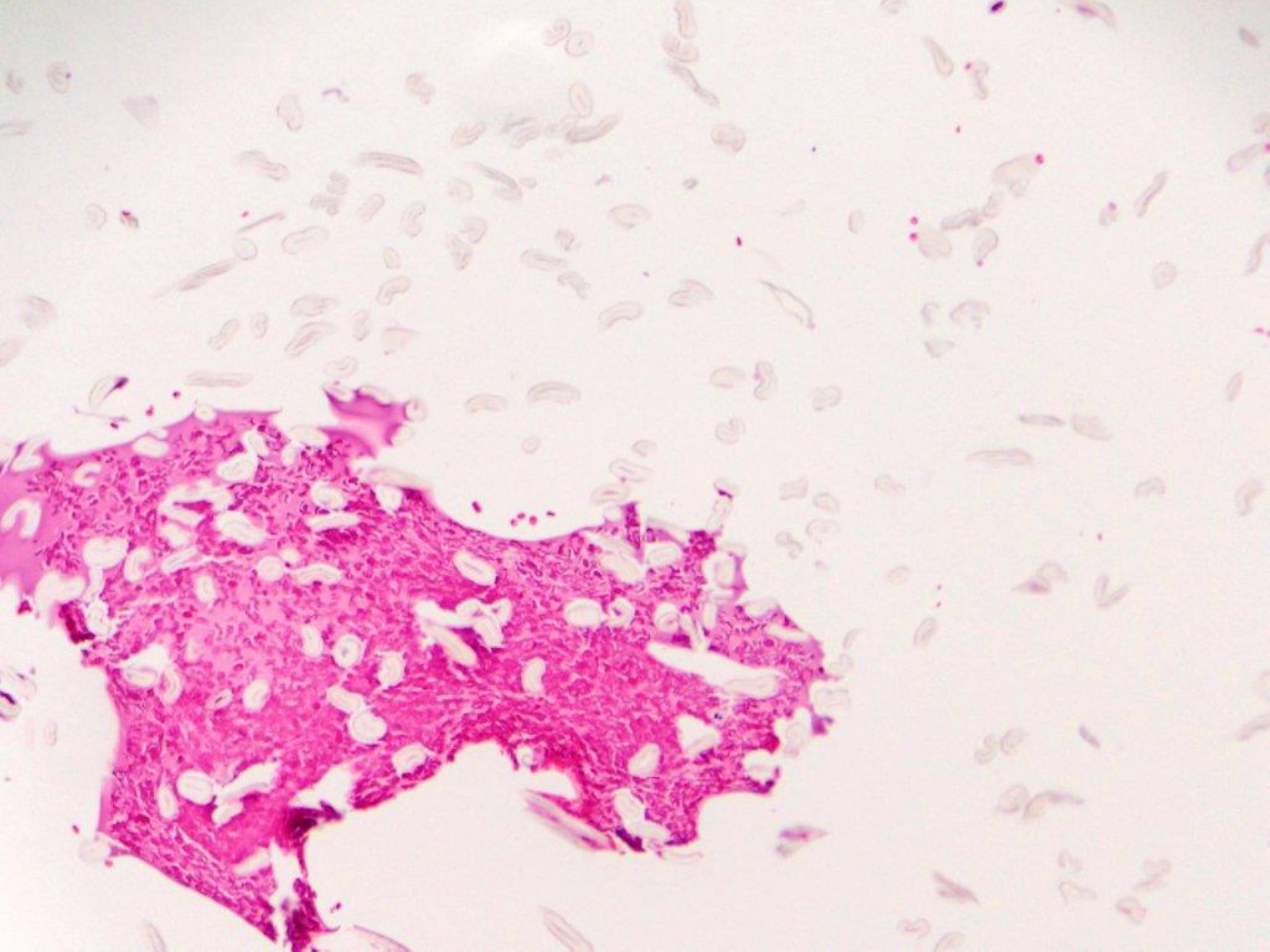


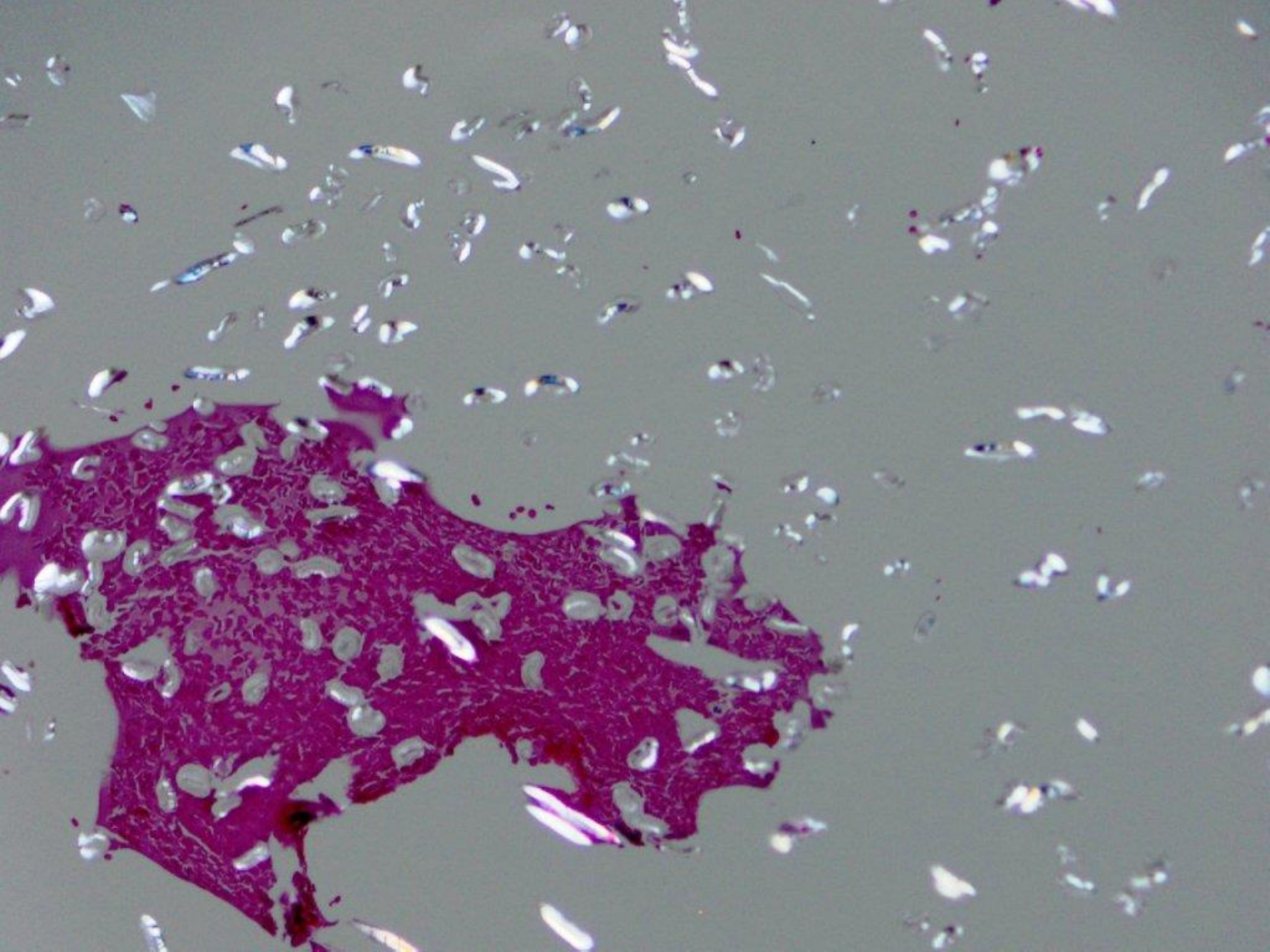


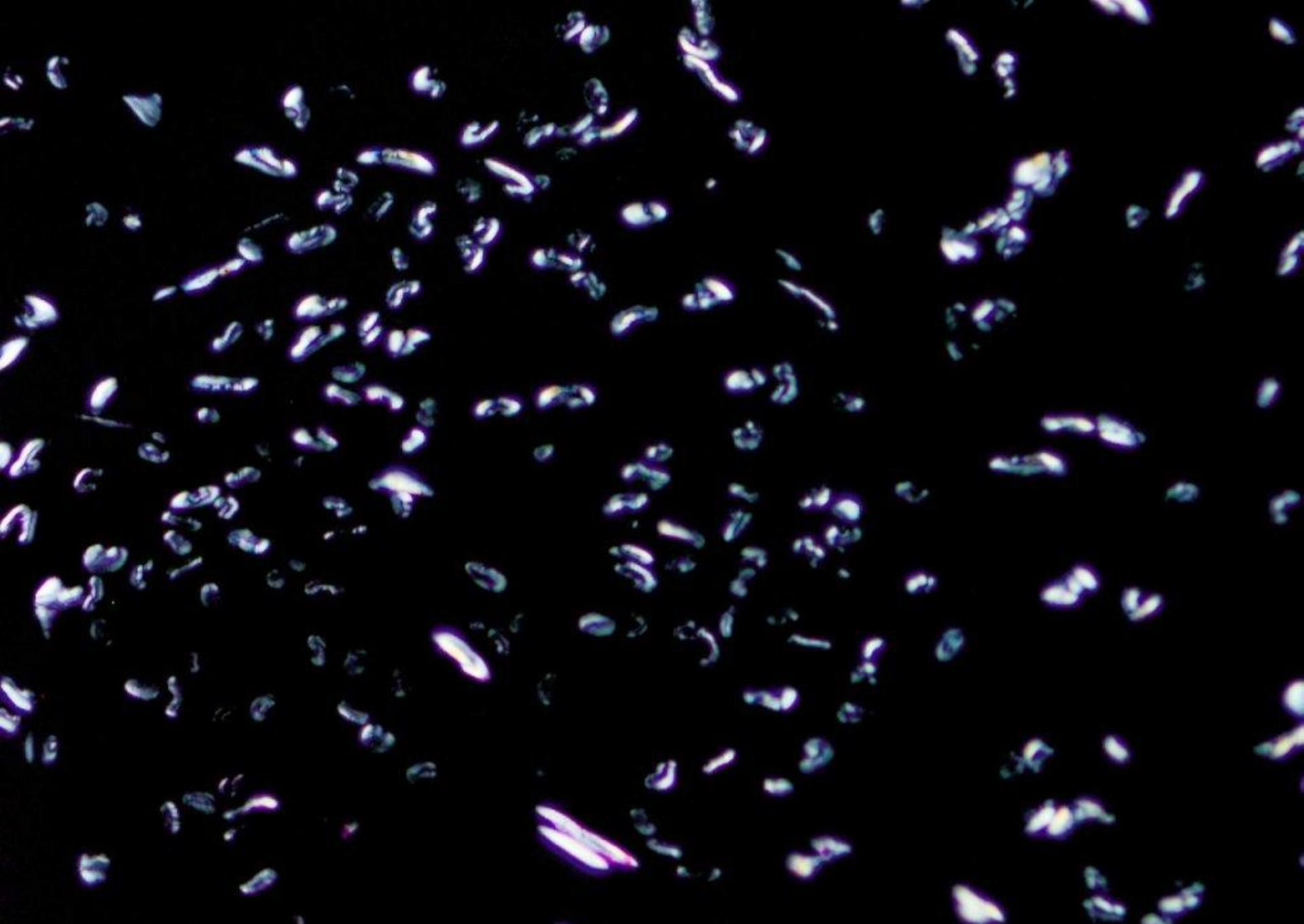


combined peripheral ossifying fibroma/pyogenic granuloma

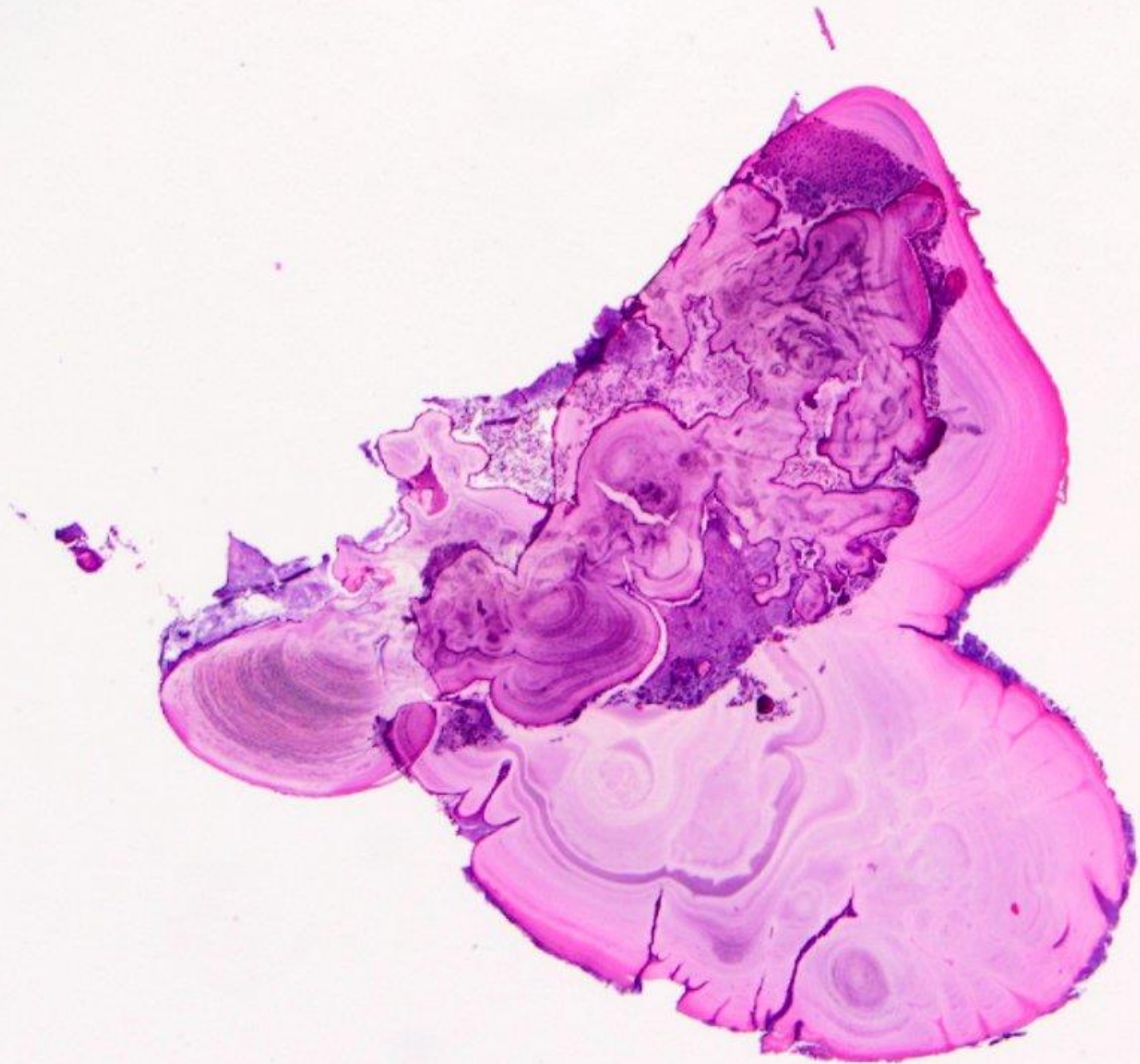


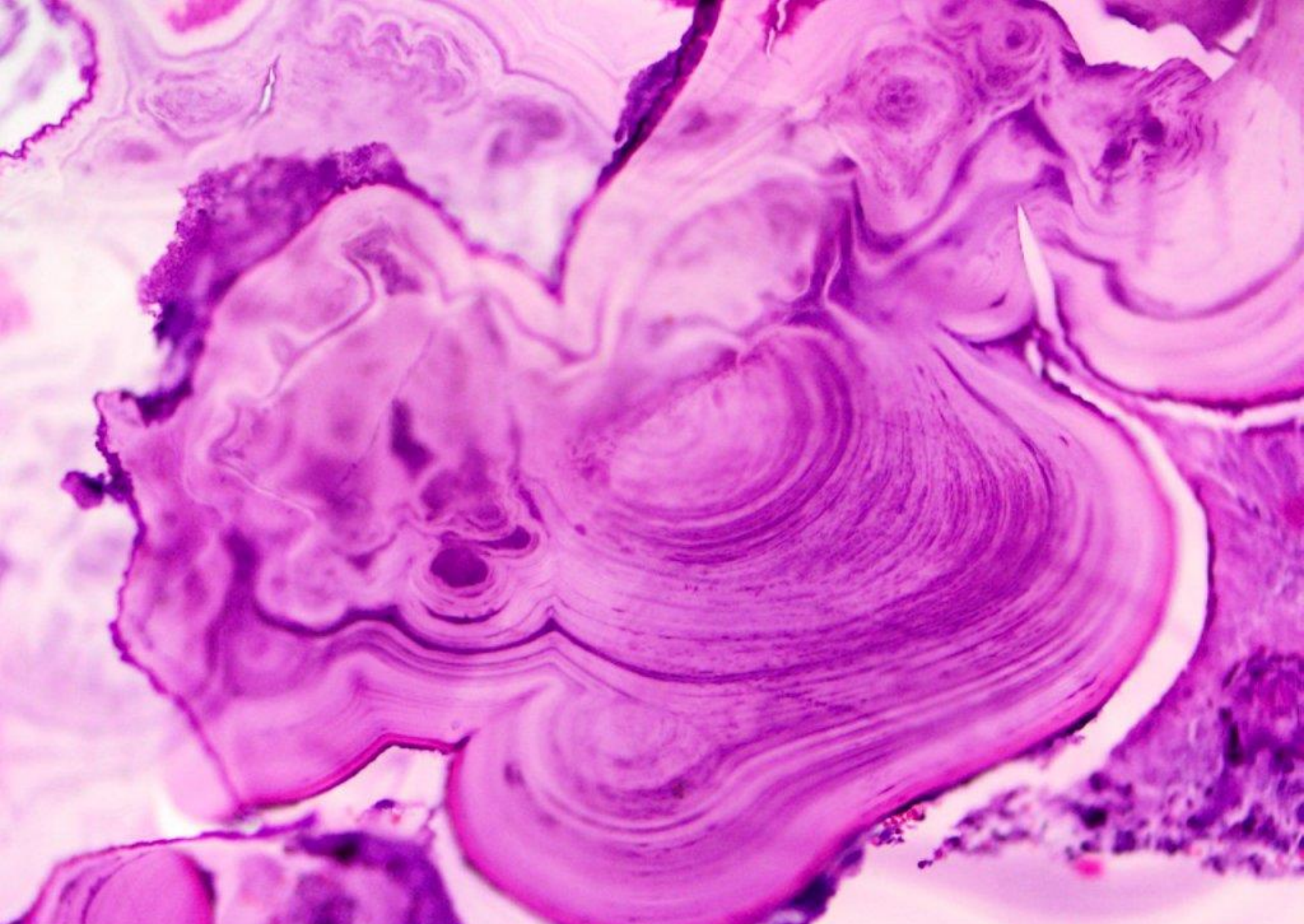




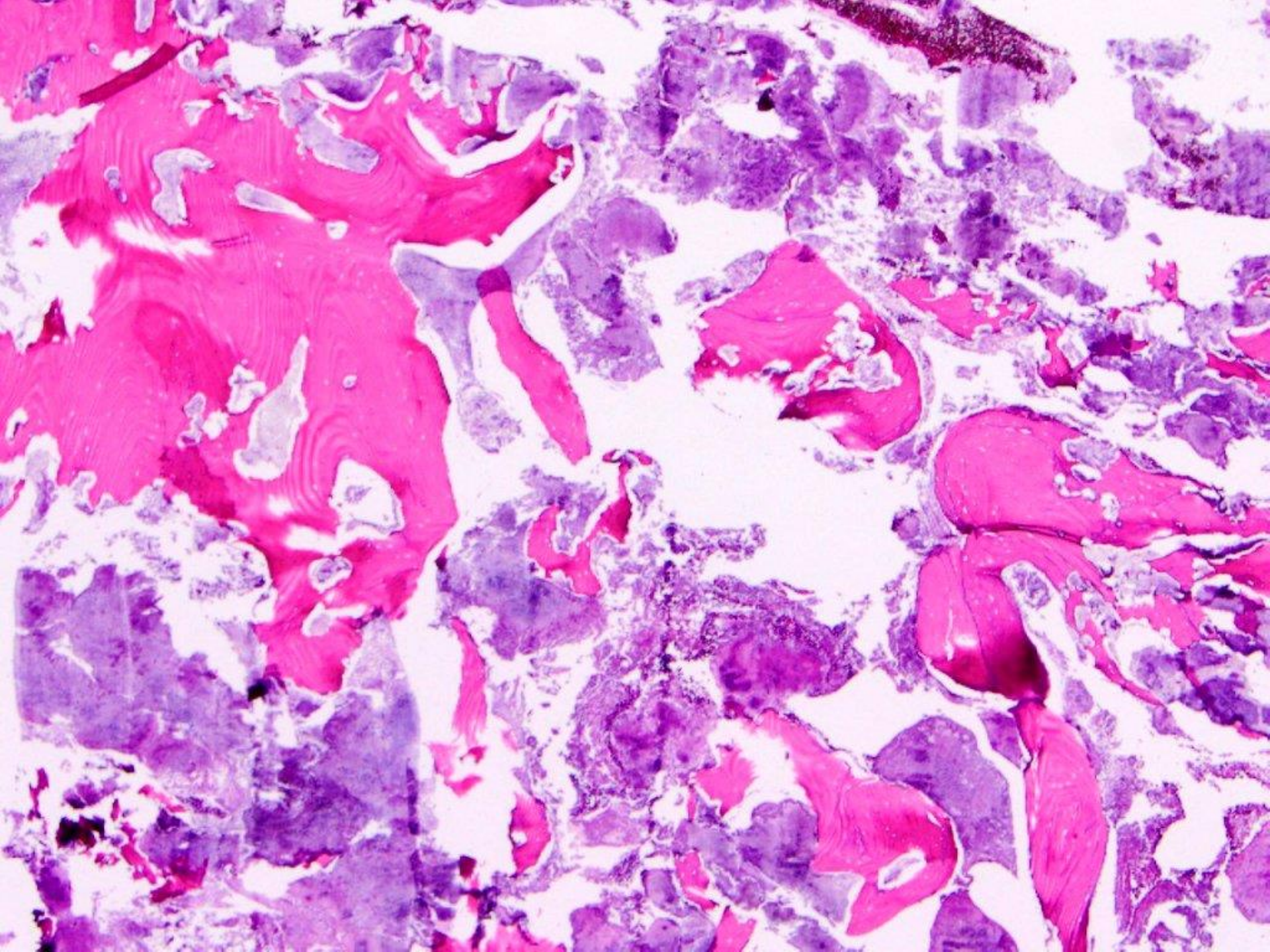


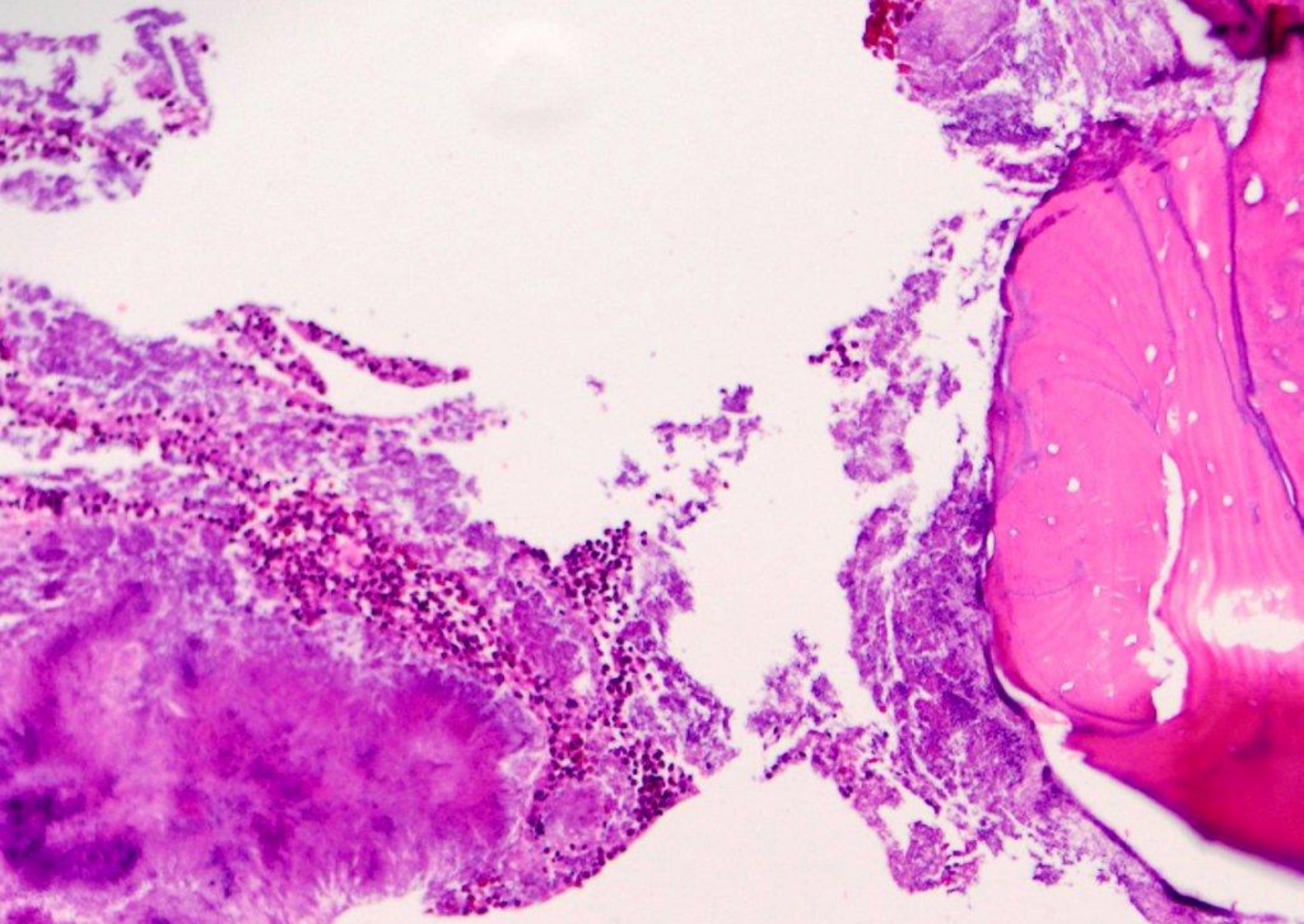
polarizable foreign body



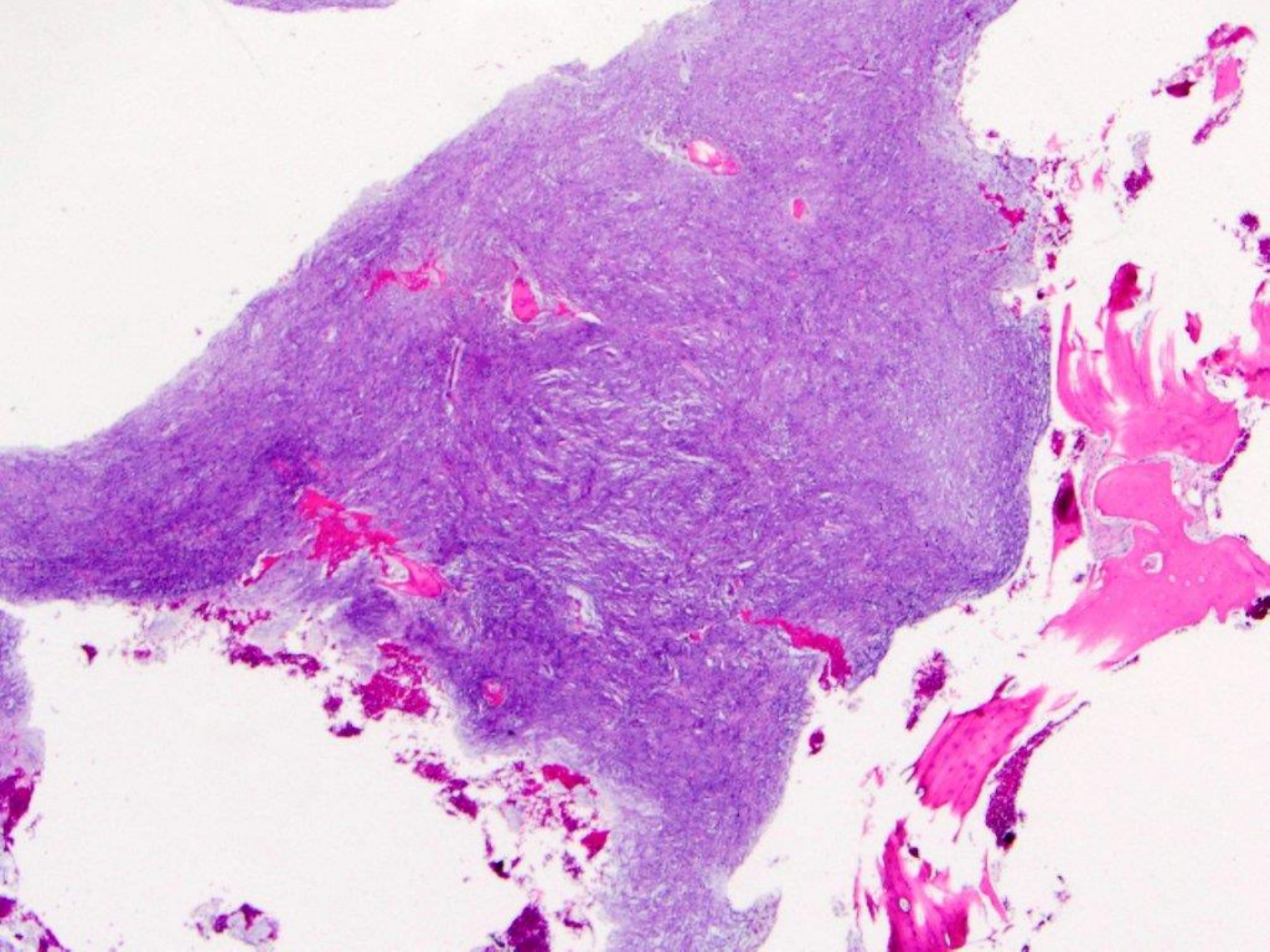


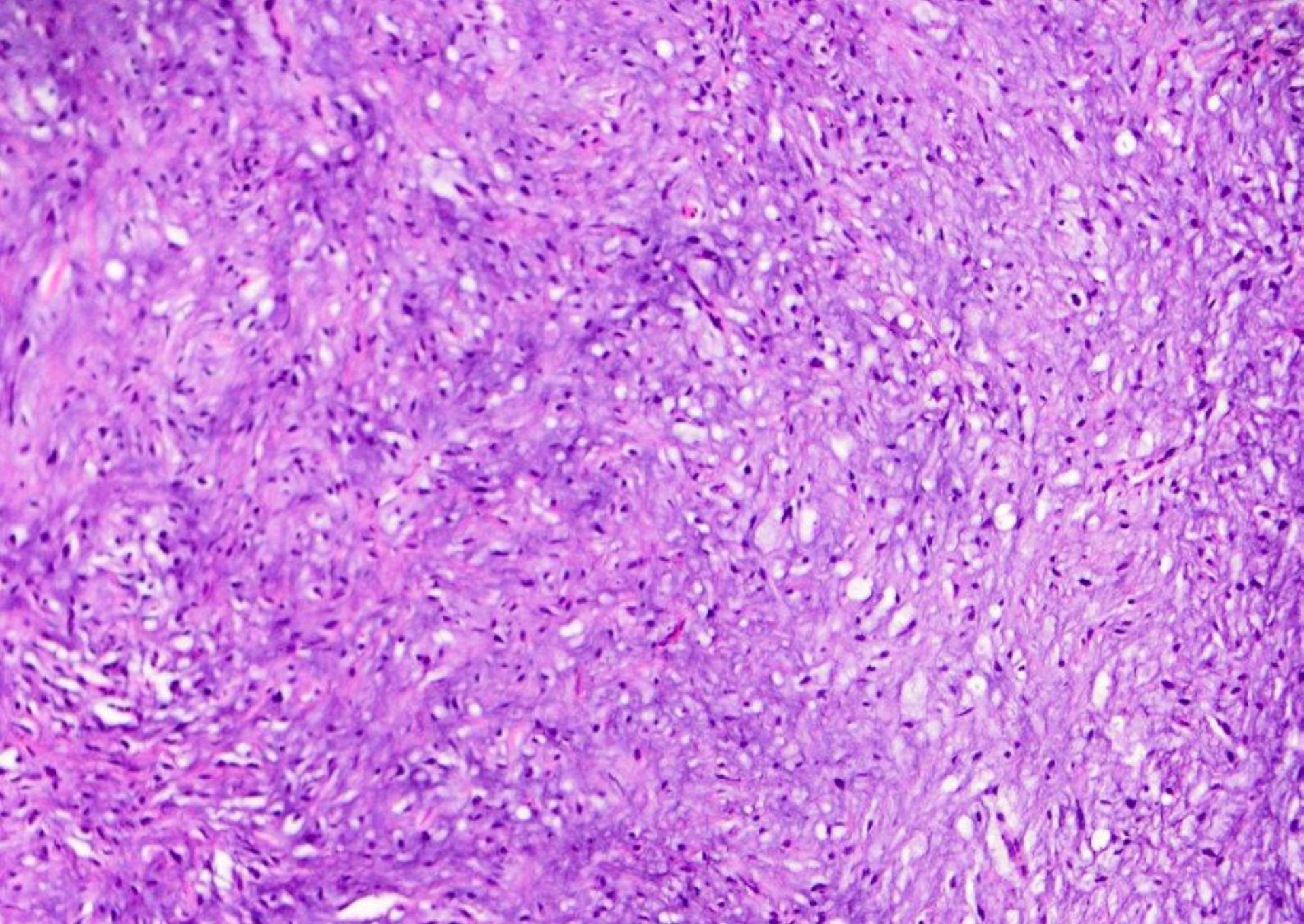
sialolith





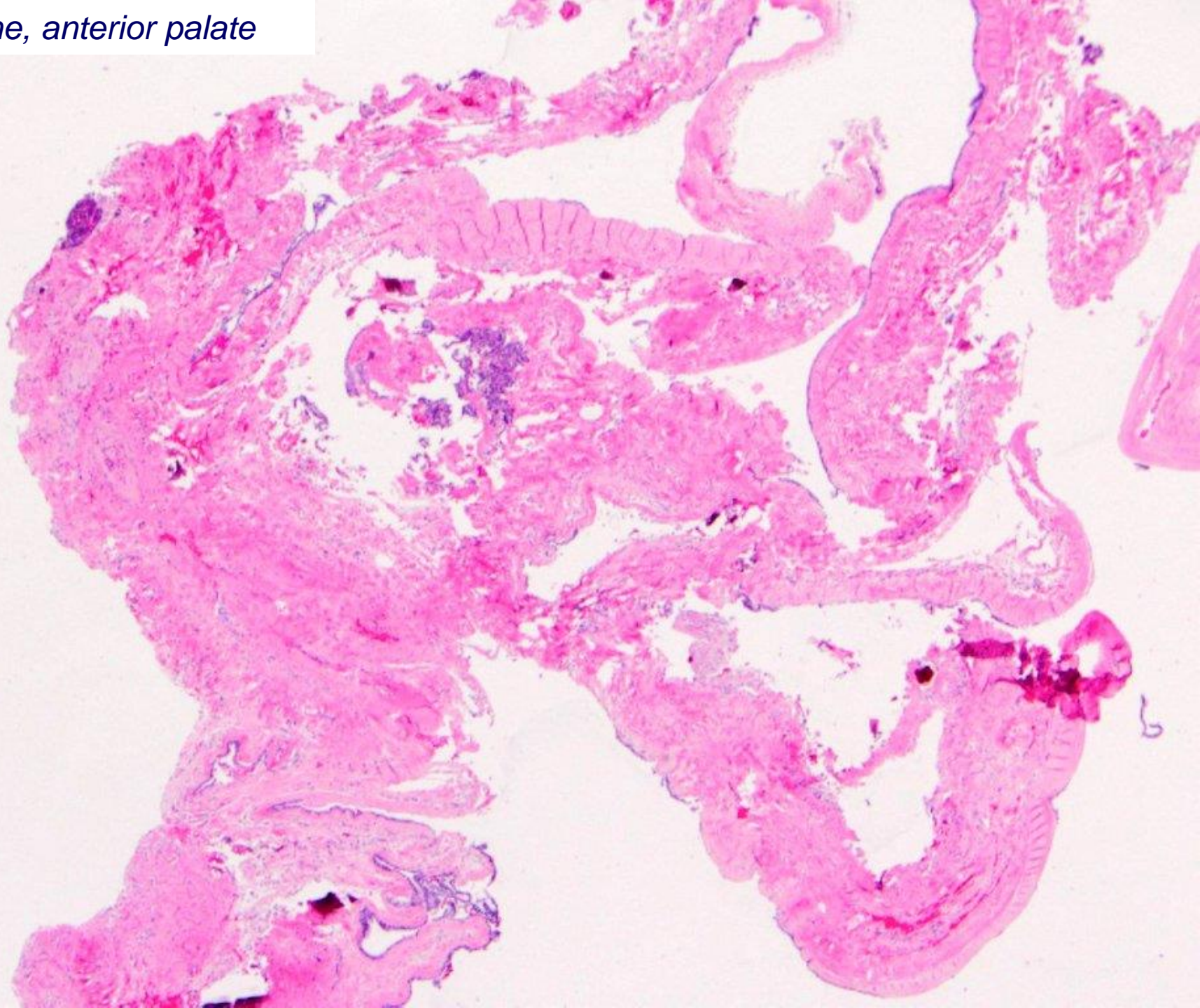
BRONJ



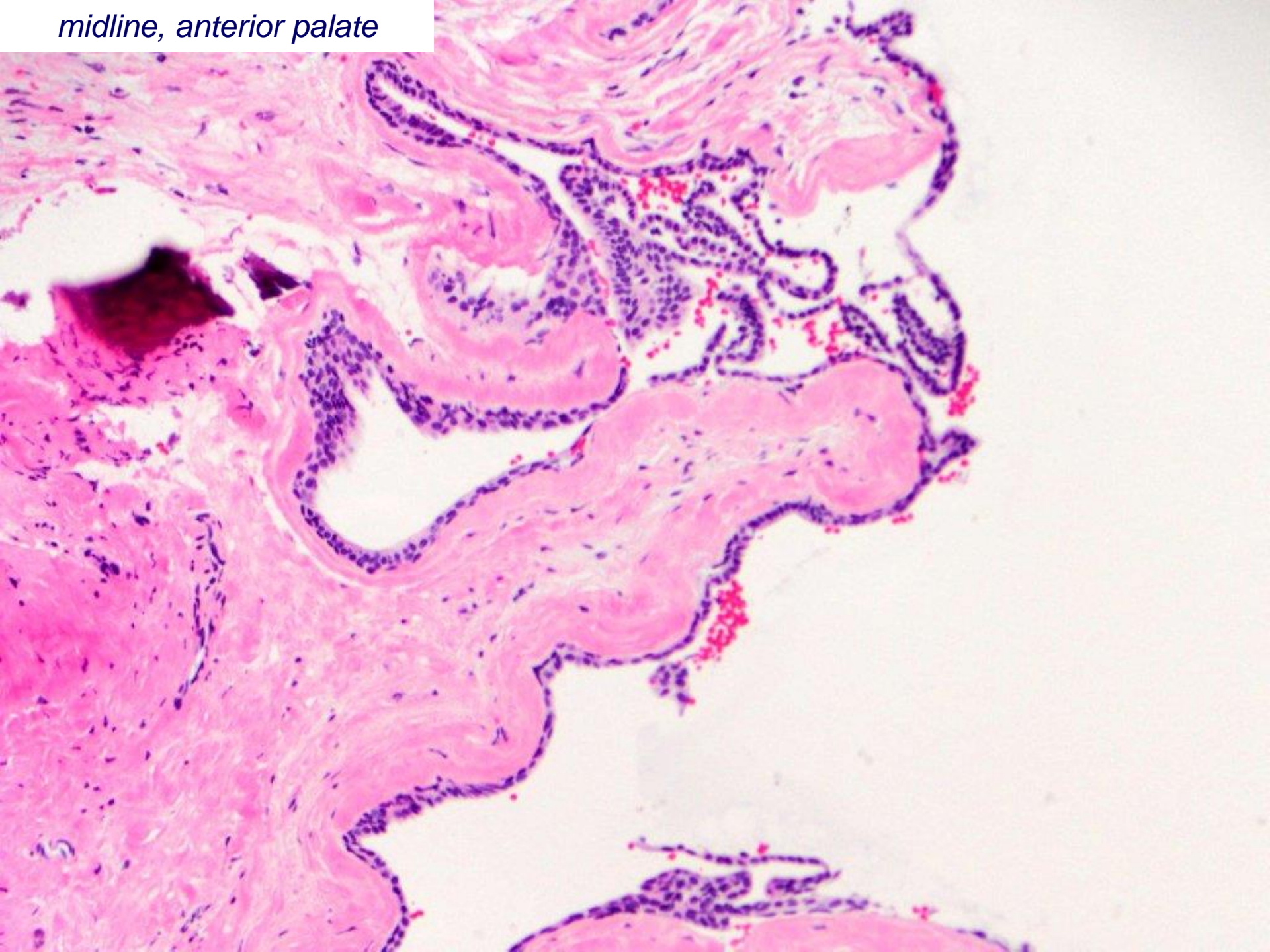


odontogenic myxoma

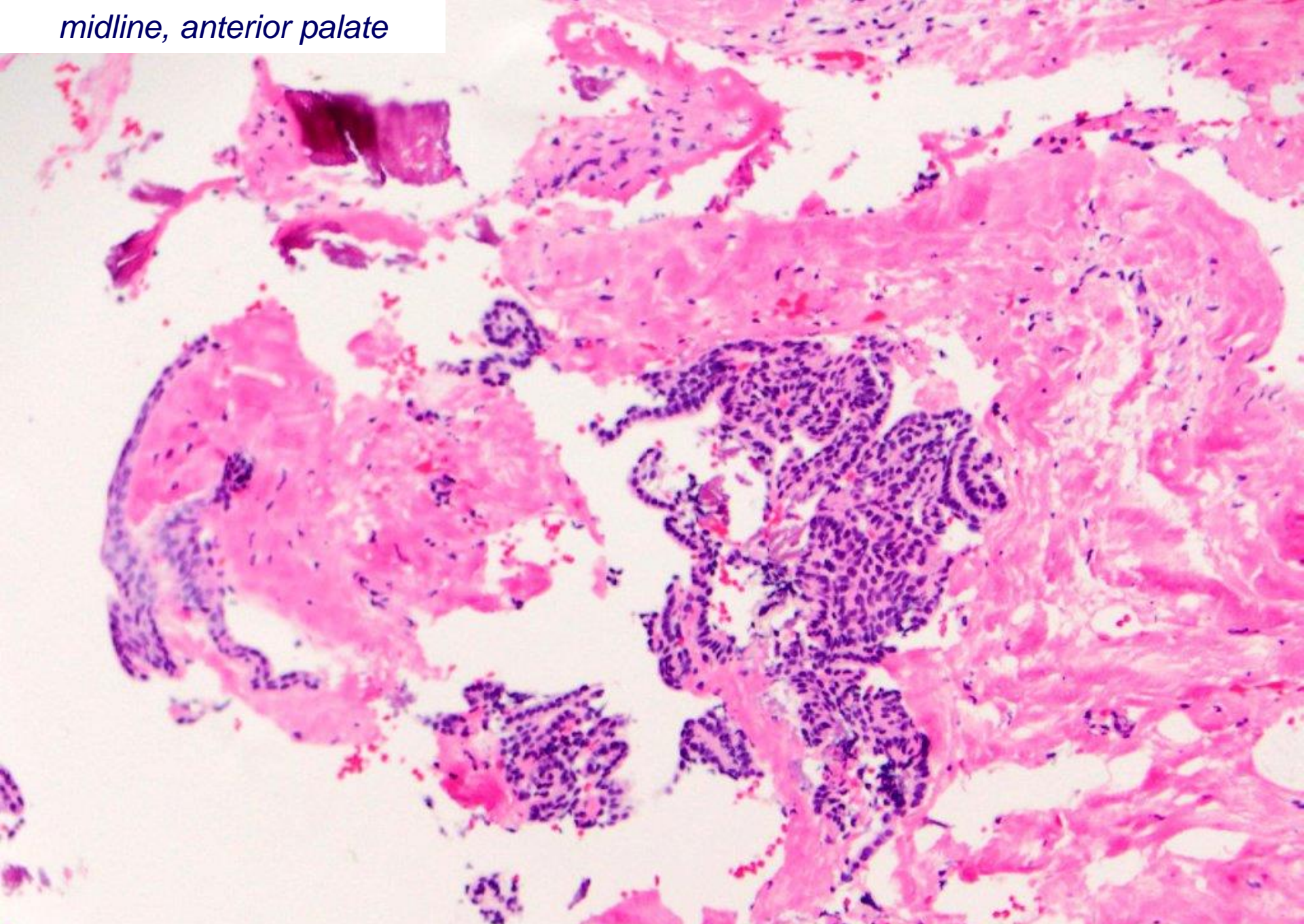
midline, anterior palate



midline, anterior palate

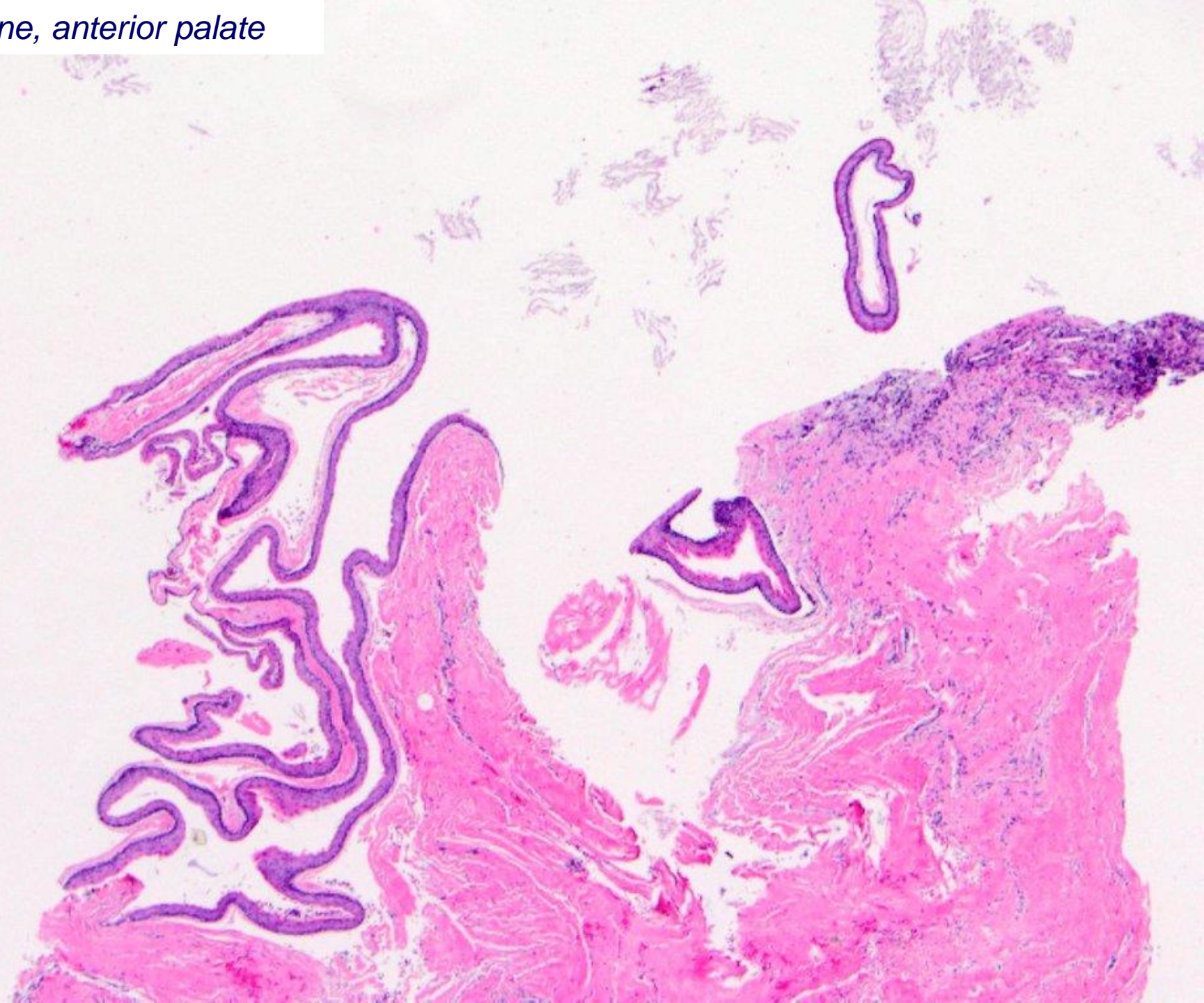


midline, anterior palate

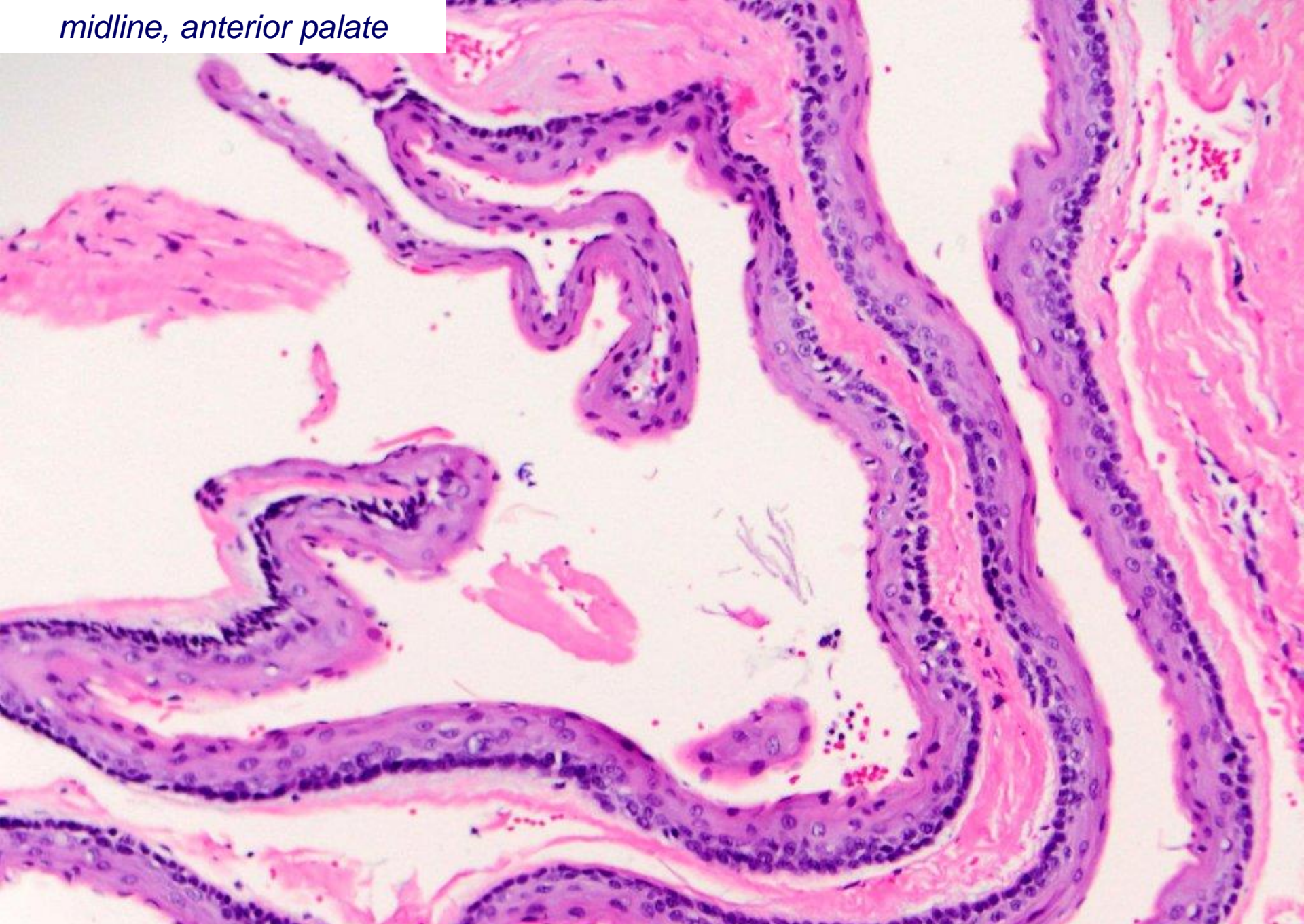


nasopalatine duct cyst

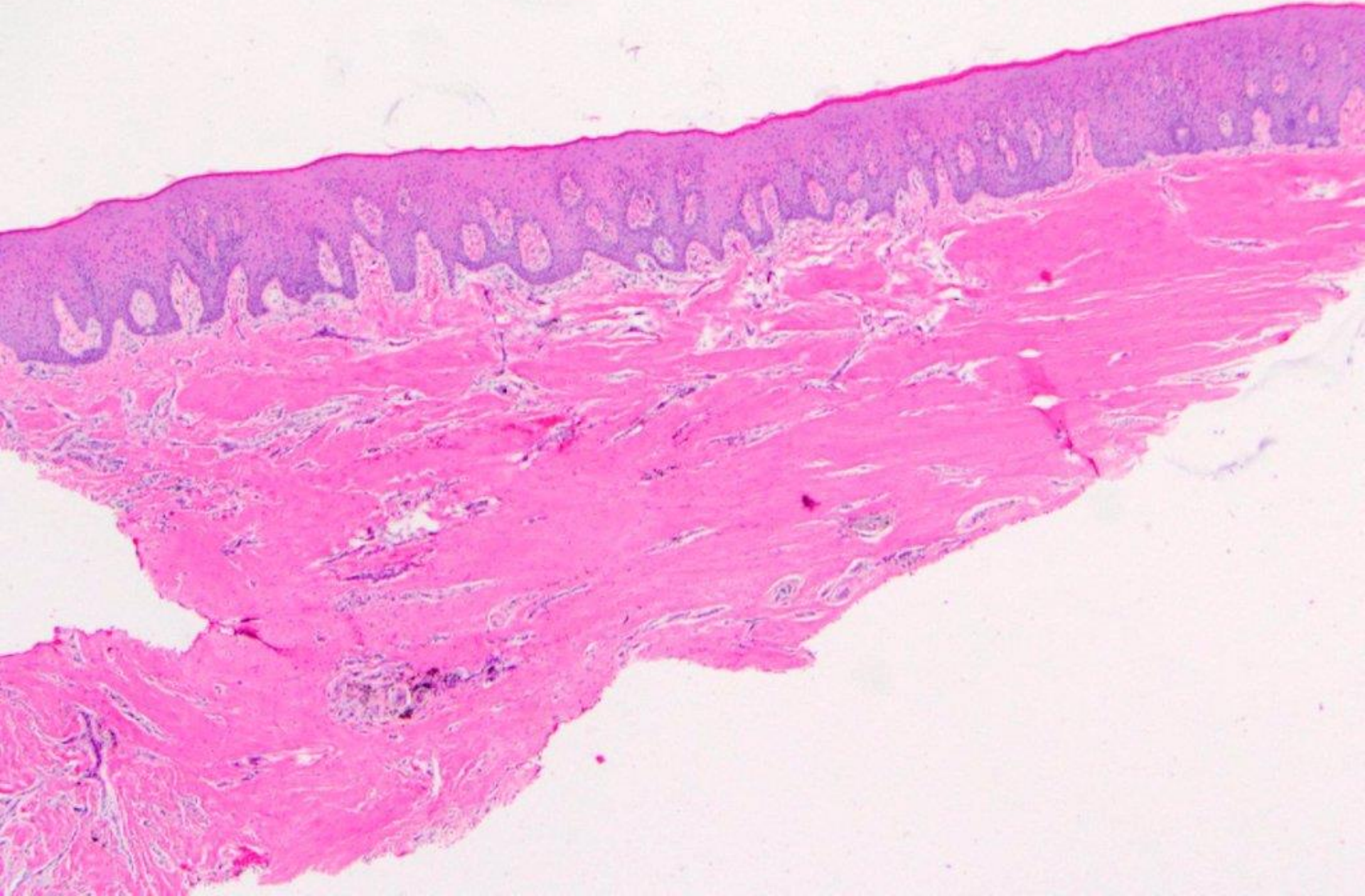
midline, anterior palate

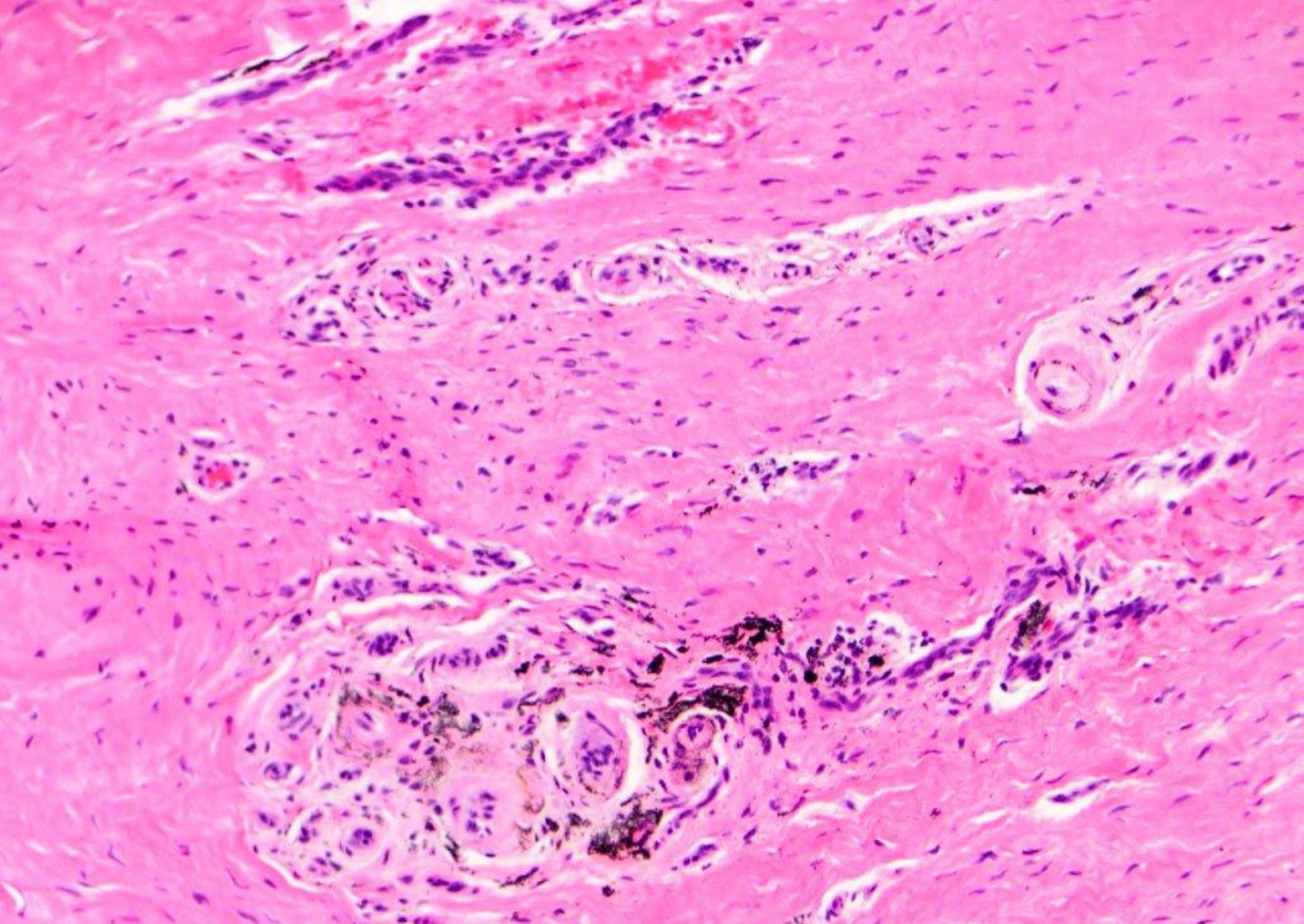


midline, anterior palate



odontogenic keratocyst (keratocystic odontogenic tumor)





exogenous pigmented foreign material c/w amalgam tattoo